

Reprinted from OPHTHALMOLOGY, Vol 103, No 8, August 1996
Published by Lippincott-Raven Publishers Printed in U S A
Copyright © 1996 by the American Academy of Ophthalmology, Inc

Excimer Laser Phototherapeutic Keratectomy

Surgical Strategies and Clinical Outcomes

Peter S Hersh, MD, Yochanan Burnstein, MD, Jonathan Carr, MD,
Gupta Etwaru, MD, Martin Mayers, MD

Excimer Laser Phototherapeutic Keratectomy

Surgical Strategies and Clinical Outcomes

Peter S. Hersh, MD,^{1,2,3,4} Yochanan Burnstein, MD,³ Jonathan Carr, MD,²
Gupta Etwaru, MD,³ Martin Mayers, MD^{2,3}

Purpose: To assess the different strategies and analyze clinical outcomes of excimer laser phototherapeutic keratectomy (PTK) for a variety of superficial corneal disorders.

Methods: Twenty-eight eyes of 26 patients with one of five general categories of corneal disorders were treated with a variety of PTK techniques. Patients were assessed for preoperative and postoperative corneal thickness, uncorrected and best spectacle-corrected visual acuity, refractive changes, corneal topography and astigmatism, and results of a subjective patient questionnaire. Follow-up ranged from 6 to 30 months.

Results: The average number of laser pulses was 418, with a mean decrease in corneal thickness of 31 μm . Uncorrected visual acuity improved in 20 eyes and decreased in 5. Best spectacle-corrected visual acuity improved in 20 eyes and decreased in 5; two patients had two Snellen lines of best-corrected vision loss. Nineteen patients (21 eyes) noted symptomatic improvement. Corneal topography improved in 17 eyes and worsened in 1. The average refractive shift was +1.4 diopters; patients undergoing general PTK, PTK combined with mechanical superficial keratectomy, and superficial scar removal had greater degrees of hyperopic shift. Complications were rare. Two patients who did not appreciate adequate improvement in vision after PTK underwent subsequent penetrating keratoplasty.

Conclusions: A number of PTK techniques are available to treat particular corneal disorders. Planning of surgical strategy is guided by careful patient selection which will minimize optical side effects and optimize visual outcome and subjective symptomatology after the PTK procedure. *Ophthalmology* 1996;103:1210-1222

Originally received: July 25, 1995

Revision accepted: April 16, 1996

¹ Department of Ophthalmology, UMDNJ-New Jersey Medical School, Newark

² Department of Ophthalmology, Albert Einstein College of Medicine/Montefiore Medical Center, Bronx

³ Bronx-Lebanon Hospital Center, Bronx

⁴ Cornea and Laser Institute, Hackensack University Medical Center, Hackensack, New Jersey

Supported in part by an unrestricted grant to the Department of Ophthalmology, UMDNJ-New Jersey Medical School, Newark, and Montefiore Medical Center, Bronx, from Research to Prevent Blindness, Inc, New York, New York

Dr. Hersh is a principal investigator and consultant for Summit Technology, Inc. Drs. Burnstein, Carr, Etwaru, and Mayers have no proprietary interest in the development or marketing of any of the methods or instruments described.

Reprint requests to Peter S. Hersh, MD, Department of Ophthalmology, UMDNJ-New Jersey Medical School, 90 Bergen St, Newark, NJ 07103.

The excimer laser may provide a novel modality in treating a number of superficial corneal disorders. The United States Food and Drug Administration recently approved two manufacturers' laser for use in the phototherapeutic keratectomy (PTK) procedure; thus, PTK is likely soon to become a more widespread technique in corneal surgery.

Whether PTK is used alone or as an adjunctive strategy in traditional mechanical superficial keratectomy techniques, a number of disorders affecting the corneal surface may be treated successfully by taking advantage of the excimer laser's ability to meticulously remove superficial corneal tissue. These include a variety of corneal degenerations and dystrophies, corneal irregularities, and superficial scars. Although some of these conditions, heretofore, could be treated by mechanical superficial keratectomy techniques,^{1,2} PTK may minimize tissue removal and surgical trauma. The smoother stromal surface thus

promised by photoablation may improve surface optical topography, improve postoperative corneal clarity and decrease postoperative scarring, and facilitate subsequent epithelial adhesion. Moreover, superficial corneal disorders that, in some patients, would otherwise require lamellar or penetrating keratoplasty may be amenable to treatment with the PTK procedure.

Unlike the excimer laser photorefractive keratectomy (PRK) technique, PTK surgical strategies will vary significantly with different corneal disorders, and the clinical goals of the procedure may, likewise, vary, depending on the patient's symptoms. In addition, the side effects and complications of PTK may differ from both PRK and those of mechanical superficial keratectomy. In this study, we describe the surgical strategies, clinical outcomes, and complications of PTK for a number of corneal disorders.

Patients and Methods

Study Design

As part of a multicenter clinical study, a consecutive series of 28 eyes of 26 patients underwent the PTK procedure for one of five general categories of corneal disorders: (1) diffuse superficial opacities and irregularities (e.g., corneal dystrophies), (2) diffuse depositions and excrescences (e.g., band keratopathy), (3) focal excrescences and nodules such as Salzmann nodular dystrophy, (4) superficial corneal stromal scars less than 100 μm deep, and (5) epithelial basement membrane dystrophy with recurrent epithelial erosions or visual disability. All procedures were performed by the senior author (PH). Entry criteria conformed to the guidelines of the United States Food and Drug Administration under an Investigational Device Exemption granted to Summit Technology, Inc. Twenty-six patients, 17 women and 9 men, were enrolled in the study. Patients ranged in age from 26 to 81 years (mean, 51 years). Follow-up ranged from 6 to 30 months. Preoperative diagnoses are listed in Table 1. Indications for treatment included poor best spectacle-corrected visual acuity, glare and photophobia, ocular surface discomfort, recurrent epithelial erosions, and monocular diplopia.

Informed consent was obtained from all patients after the procedure had been explained fully. Preoperative and follow-up visits included a detailed ophthalmologic examination, keratometry with both manifest and cycloplegic refractions by two independent observers, visual acuity under controlled lighting conditions using an Early Treatment Diabetic Retinopathy Study chart, glare testing with the Brightness Acuity Tester (Mentor 0 & 0, Norwell, MA), contrast sensitivity (Vectorvision, Dayton, OH), computerized corneal topography (EyeSys Laboratories, Houston, TX), and anterior segment photography. Corneal thickness was determined by ultrasonic pachymetry (Sonogage, Cleveland, OH). The depth of corneal opacities was estimated by slit-lamp biomicroscopy. Average follow-up time was 1 year.

Phototherapeutic keratectomy was performed with the Summit OmniMed/ExciMed excimer laser system (Sum-

Table 1. Phototherapeutic Keratectomy: Preoperative Diagnoses

Preoperative Diagnosis	No. of Eyes
Corneal scarring	8
Salzmann degeneration	4
Reis-Buckler dystrophy	5
Lattice dystrophy	1
Band keratopathy	3
Recurrent erosion syndrome	5
Contact lens-induced keratopathy	1
Epithelial basement membrane dystrophy	1

mit Technology, Inc, Waltham, MA). Laser parameters included a repetition rate of 10 Hz, fluence of 180 mJ/cm², and pulse duration of 14 ns, resulting in an estimated ablation rate of corneal stromal tissue of 0.25 μm per pulse. Beam size ranged from 1.5 to 6.0 mm.

Visual acuity was measured on a logMAR scale.³ Computer-assisted videokeratography was evaluated by two independent masked observers and judged for improvement or worsening.⁴ For this analysis, both the videokeratoscope image and the computer-generated topography maps were examined for changes in corneal surface irregularity between the preoperative and final postoperative examinations. Subjective patient improvement was determined both by a patient questionnaire and physician assessment at the time of the examination. Data were entered into a commercial database program (Excel 4.0, Microsoft, Seattle, WA) for analysis.

Techniques of Phototherapeutic Keratectomy

General Large-area Phototherapeutic Keratectomy. This technique is used for diffuse superficial corneal opacities and irregularities such as Reis-Bucklers dystrophy, lattice and other corneal dystrophies, generalized superficial keratopathies, and other extensive corneal surface irregularities (Fig 1). Eight eyes were treated in this group: five with Reis-Bucklers dystrophy, one with lattice dystrophy, one with extensive epithelial basement membrane dystrophy, and one with contact lens-associated keratopathy.

An irregular epithelium is removed carefully using dry cellulose sponges and the back of a spatula-type blade. Care is taken to leave peripheral corneal and limbal epithelium intact to provide a reservoir of cells for subsequent epithelialization.⁵ In contrast, if the corneal epithelial surface appears to be smoothing the surface of a more irregular underlying stroma, it is left in place and removed with the laser.

For general large-area PTK, a wide diameter spot size (e.g., 5–6 mm) is selected. Important for the PTK procedure, a nonsmooth corneal surface is "spackled" with methylcellulose 1% to fill in irregularities, thereby smoothing the surface to be ablated.^{6,7} The viscosity of methylcellulose 1% generally is appropriate to fill in the

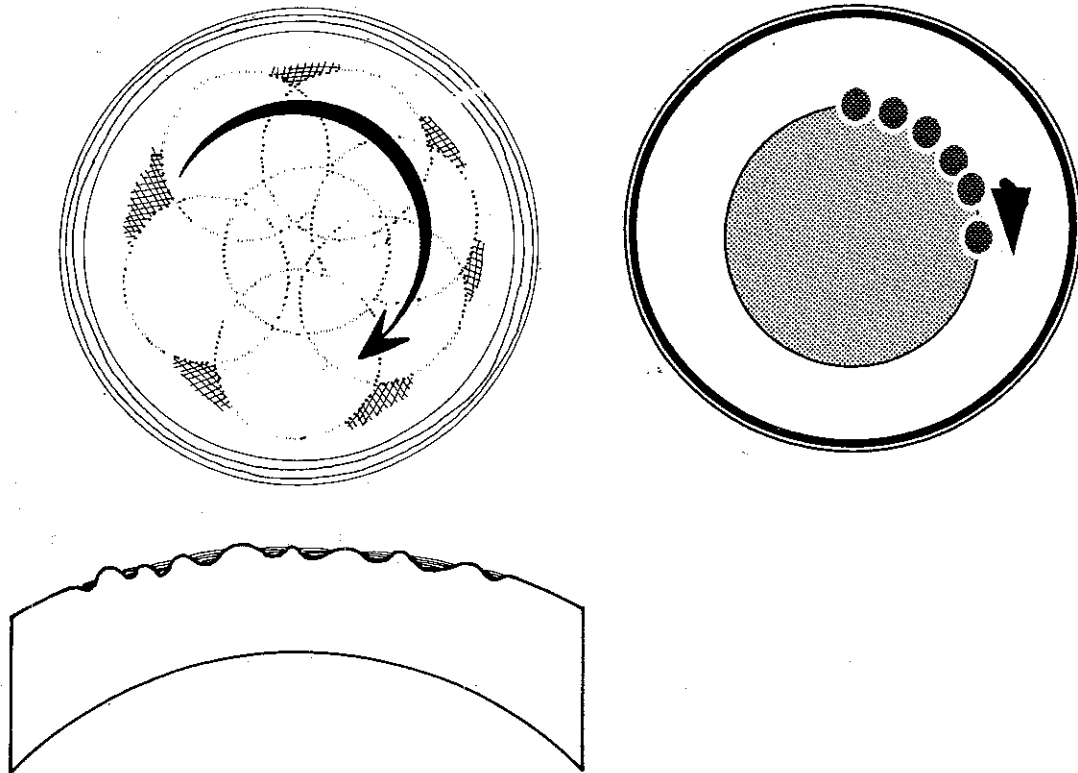


Figure 1. Technique of general clearing and smoothing procedure. **Left,** schematic shows methylcellulose filling in valleys of an irregular corneal surface. Annular movement of an eye under laser beam by gentle rotation of the patient's head smooths and clears a large surface area of the cornea. **Right,** at the conclusion of the procedure, smaller beam diameter may be applied in an annular fashion to further smooth the edge and prevent corneal flattening.

valleys of an irregular surface, whereas lower concentrations may flow too freely, and higher concentrations tend to completely mask the incoming beam.

After focusing the laser using crossing helium-neon aiming beams,⁸ the laser procedure is begun. With the patient gazing at the laser's fixation light, the footpedal is depressed and lasing proceeds as the eye is rotated by gently moving the patient's head. This is in contrast to the "point-and-shoot" technique used in PRK; in PTK, the annular eye motion may help blend the edge of the ablation zone, avoiding the creation of a stromal crater with a sharp perpendicular edge with its consequent distortion of corneal surface topography.⁹

During the procedure, a blue fluorescence signals that epithelium is being ablated.¹⁰ This fluorescence disappears upon reaching the corneal stroma. In contrast, methylcellulose tends to whiten and bubble upon ablation and the normal loud snapping sound of the laser-tissue interaction is muffled, indicating partial masking of the incoming beam. Such sensory feedback thus can guide the surgeon during the procedure.

The procedure is interrupted at relatively frequent intervals and the patient is examined at the slit lamp to closely monitor the progress of the procedure and to determine additional areas to be treated. Additional methylcellulose is applied as necessary to smooth the surface as the procedure proceeds. Adequately treated areas may

be protected from further laser ablation by focally applying methylcellulose. A relatively high concentration (1% or 2.5%) is preferred because thinner solutions tend to flow from the intended area. The beam diameter may be changed as necessary to touch-up remaining areas of pathology and to avoid unintended ablation of areas adequately treated.

To decrease irregular astigmatism, relatively more treatment may be applied to steep areas as evidenced by the videokeratography map to relatively flatten these areas.¹¹ In addition, some investigators advocate placing a midperipheral annulus of treatment using a small beam diameter (e.g., 2 mm) to steepen the overall macroscopic corneal contour, thus minimizing hyperopic shifts induced by the procedure.¹² Such an intervention may be useful if the border of the ablation zone and peripheral cornea appears abrupt. In this technique, the smaller beam is used to meticulously smooth and blend the junction of the treated and nontreated cornea.

At the conclusion of the treatment, the cornea typically has a ground-glass appearance. After epithelial healing, corneal luster is regained.

Combined Mechanical Superficial Keratectomy and Phototherapeutic Keratectomy. In corneal disorders where abnormal tissue may be excimer ablation resistant, such as in calcific band keratopathy¹³ or in some corneal scars,¹⁴ or where there is abundant deposition of abnormal

material, such as in pterygia or climatic droplet keratopathy, the PTK procedure may be combined with mechanical superficial keratectomy (Fig 2).¹⁵ After epithelial removal, the cleavage plane between abnormal tissue and stroma is identified by blunt dissection; a dry cellulose sponge is a useful, atraumatic instrument for this step. The abnormal tissue then is peeled and stripped using dry sponges and fine tissue forceps. Sharp dissection may be necessary to remove firmly adherent tissue, always remaining parallel to the cleavage plane to avoid deeper stromal damage.^{2,16}

After completion of mechanical superficial keratectomy, PTK is accomplished using the standard techniques of the general large-area PTK procedure. When the corneal pathology is localized and other areas of the cornea are normal, only the affected area will be treated with the laser; in such cases, a smaller beam diameter may be used for general smoothing, or the focal smoothing technique as described below may be used.

Focal Smoothing. Discrete corneal excrescences such as Salzmann nodular degeneration and fibrous nodules in keratoconus^{17,18} may be treated directly with the excimer laser beam (Fig 3). The amount of elevation is first estimated by slit-lamp examination. In some patients, an optical pachymeter may be used to directly measure the elevation. The anticipated number of laser pulses can then be calculated conservatively (number of pulses = elevation in microns \times 4). The epithelium over the area to be treated

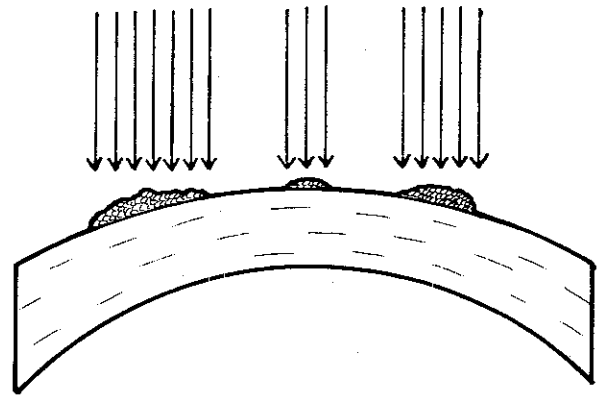


Figure 3. The technique of focal smoothing is shown using the excimer laser. The laser beam diameter is adjusted per the size of the nodular elevation. The epithelium is left in place over normal areas of cornea, protecting such areas from ablation.

is removed mechanically, again with blunt dissection. The surrounding epithelium, however, is left intact to shield normal corneal stroma from ablation. Surrounding normal areas also may be masked with methylcellulose. The laser spot size is chosen to coincide with the nodule being treated. The laser is aimed at the nodule and treatment is then applied to smooth the elevated area. The patient is examined frequently at the slit lamp until the surface

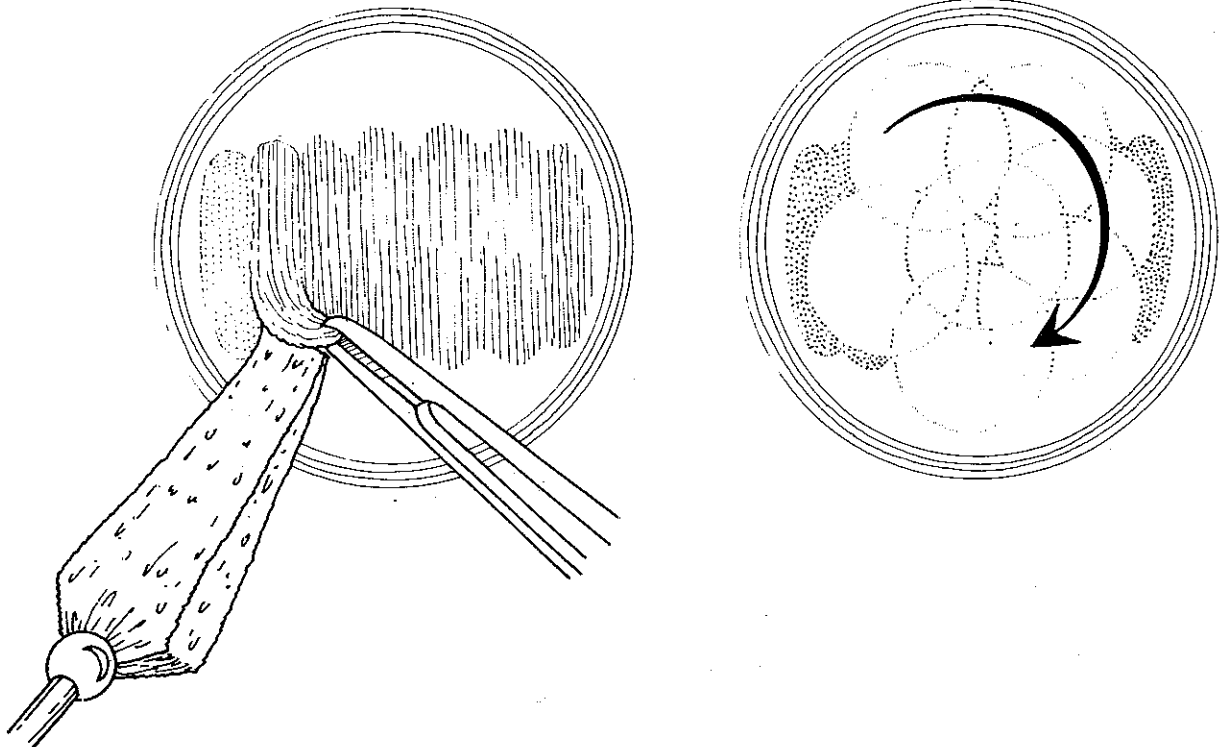


Figure 2. Technique of combined mechanical superficial keratectomy and phototherapeutic keratectomy. **Left,** schematic shows meticulous peeling and stripping of surface deposition, avoiding sharp dissection. **Right,** phototherapeutic keratectomy then is performed using the general large area smoothing strategy.

is smooth. Care is taken to avoid overtreatment with consequent crater formation on the corneal surface.

Superficial Scar Removal. Focal superficial corneal scars are ablated with careful attention to the minimization of postoperative corneal topographic and refractive changes that may result from stromal tissue removal (Fig 4). Therefore, a smooth epithelium overlying the scar is left in place because it may naturally fill in surface irregularities of the scar itself, and any irregularities that subsequently develop during treatment are smoothed with methylcellulose. Importantly, direct treatment of the scar is combined with active blending of the ablation zone borders by rotating the eye during treatment as in the general PTK technique. Actual tissue ablation should be minimized to avoid postoperative corneal surface distortion; it is unnecessary to remove the entire scar from the cornea. Rather, "debulking" of the scar may give a visually satisfactory result.

Epithelial Basement Membrane Dystrophy and Recurrent Epithelial Erosion Syndrome. As with the foregoing procedures, the treatment of recurrent epithelial erosions in association with map-dot-fingerprint epithelial basement membrane dystrophy has been approved by the United States Food and Drug Administration (Fig 5). However, the treatment of recurrent erosions in the absence of the dystrophy has not yet been approved.

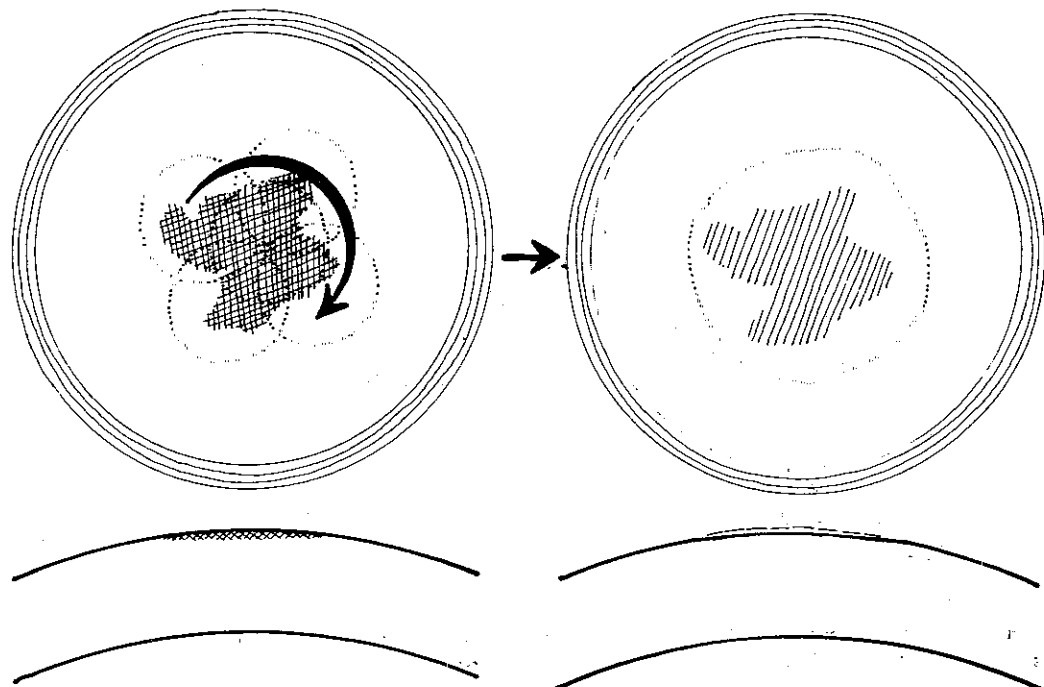
Poorly adherent epithelium overlying the area of a recalcitrant recurrent erosion is removed carefully, using a dry cellulose sponge as the primary instrument and the back of a spatula-type microsurgical blade only if necessary. Underlying reduplicated basement membrane or cellular debris is then stripped carefully, leaving a smooth surface. Forceps (0.12 mm) may be useful in this stripping technique.¹⁹ Spot size is determined by the area of ab-

normality to be treated. The laser is delivered focally for areas of 6 mm or less, and the beam diameter is set to the treatment area. Approximately 15 pulses are applied directly, resulting in a nominal ablation of 3.75 μm . When larger areas are to be treated, approximately 15 pulses per unit area are applied, and the patient's head is rotated to uniformly distribute the ablation. This technique is thought to meticulously clean and smooth the corneal surface, leaving both an optically clear cornea and smooth stromal substrate for subsequent re-epithelialization.

Postoperative Management

Postoperative care was directed toward facilitating re-epithelialization, minimizing inflammation and scarring, and avoiding infection. In general, the eye was patched overnight with a topical antibiotic-steroid ointment. Oral analgesic agents were given as necessary. Topical antibiotics were continued until epithelialization was complete. Nonpreserved lubricants and a bandage soft contact lens were used if epithelialization were delayed. Topical corticosteroids were used to decrease inflammation and scarring. Except in patients treated for epithelial basement membrane dystrophy, a corticosteroid such as fluorometholone 0.1% was generally used four times daily and tapered by one drop each month. In patients with more profound surface inflammation, prednisolone acetate 1% was used. After treatment for epithelial basement membrane dystrophy, corticosteroids generally were not used. In one patient treated for scarring secondary to herpes simplex keratitis, oral acyclovir (400 mg 3 times daily) and topical antiviral agents were administered perioperatively to avoid reactivation of the virus.²⁰

Figure 4. The technique of superficial scar removal is shown. Schematic shows annular motion of the eye under the laser beam by gentle rotation of the patient's head. The scar is removed while a blend zone is created at the junction with the untreated cornea. Treatment should be minimized to avoid postoperative changes in the corneal topography.



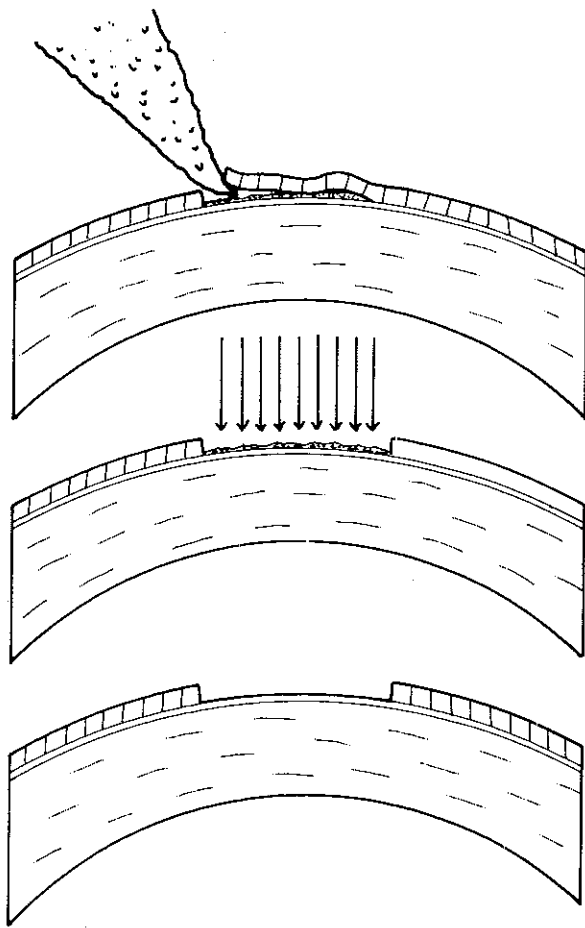


Figure 5 The technique of phototherapeutic keratectomy for recurrent corneal epithelial erosions secondary to epithelial basement membrane abnormalities is shown. Top, dysadherent epithelium is stripped gently with a dry cellulose sponge. Center, the excimer laser beam is applied focally for approximately 15 pulses for each unit area. Bottom, at the conclusion of the procedure, Bowman layer is smooth without abnormal overlying basement membrane, which affords an appropriate substrate for subsequent re-epithelialization.

Results

Laser Pulses and Pachymetry. The number of laser pulses ranged from 15 in patients with epithelial basement membrane dystrophy and recurrent erosion syndrome to 1095 in a patient with Reis-Bucklers dystrophy. The overall average number of pulses applied was 418; the average was 643 in the general PTK group ($n = 8$), 498 in the superficial keratectomy group ($n = 3$), 36 in the epithelial basement membrane dystrophy group ($n = 5$), 524 in the superficial scar group ($n = 5$), and 296 in the focal treatment group ($n = 7$). Preoperative corneal thickness ranged from 470 to 704 μm (mean, 560 μm). Postoperative values ranged from 432 to 611 μm (mean, 529). An overall average of 31 μm of tissue was removed during the procedure in general; the average amount of tissue removed was 46 μm in the general PTK group ($n = 8$), 110 μm in the superficial keratectomy group ($n = 3$), 1

μm in the epithelial basement membrane dystrophy group ($n = 5$), 69 μm in the superficial scar group ($n = 3$), and 36 μm in the focal treatment group ($n = 7$).

Visual Acuity. Preoperative and postoperative uncorrected and best-corrected visual acuities are summarized in Figures 6 and 7. Uncorrected visual acuity improved in 20 eyes (with 14 improving 2 or more Snellen lines), remained unchanged in 3, and decreased in 5 (Fig 8). Of those losing uncorrected vision, two were in the general group, one had a superficial scar, one was in the epithelial basement membrane dystrophy group, and one had undergone combined superficial keratectomy/PTK. Best spectacle-corrected visual acuity improved in 20 eyes (with 13 improving 2 or more lines), remained unchanged in 3, and decreased in 5 (Fig 9). Two patients had two Snellen lines of best-corrected visual acuity loss. Of these patients, one had an increase in cataract. The other was treated for a corneal stromal scar with consequent distortion in the postoperative corneal topography. Correction with a rigid gas-permeable contact lens, however, led to an increase in visual acuity of one line in this patient.

Subjective Patient Results. Nineteen patients (21 eyes) noted subjective improvement in their symptomatology, whereas seven reported no change. All patients with photophobia and ocular surface discomfort reported improvement. The one patient with monocular multiplopia due to Salzmann degeneration noted complete resolution of symptoms, whereas four of five patients with recurrent epithelial erosive symptoms reported improvement. Twenty-one of the 26 patients reported that they would undergo the procedure again based on their initial experience.

Corneal Topography and Astigmatism. Corneal topography was graded as improved in 17 eyes, remained unchanged in 10, and worsened in 1. This last patient had been treated for a superficial stromal scar and required a rigid contact lens to attain best-corrected visual acuity postoperatively.

Preoperative astigmatism ranged from 0 to 5.5 diopters (D) (average, 2.1 D), whereas postoperative astigmatism ranged from 0 to 5.5 D (average, 2.0 D). Thus, although individuals showed variable changes in astigmatism with the procedure, when taken as a group there was little change in keratometric astigmatism with the PTK procedure.

Refractive Shifts. Treated eyes showed a mean spherical equivalent refractive change of +1.4 D (range, -5.25 to +7.25 D) (Table 2). A hyperopic shift of 1.0 D or less was observed in ten eyes (mean change, +4.8 D). A myopic shift of 1.0 D or more was noted in three eyes (mean change, -4.76 D). Table 2 shows the refractive shifts stratified to treatment strategy. Patients receiving general large-area PTK, combined superficial keratectomy and PTK, and superficial scar removal showed mean hyperopic shifts of >2 D. Those with focal smoothing and treatment for epithelial basement membrane dystrophy showed only mild refractive changes. Of those patients with refractive shifts, a shift toward emmetropia was observed in 15 eyes, whereas a shift away from emmetropia was noted in 10 eyes.

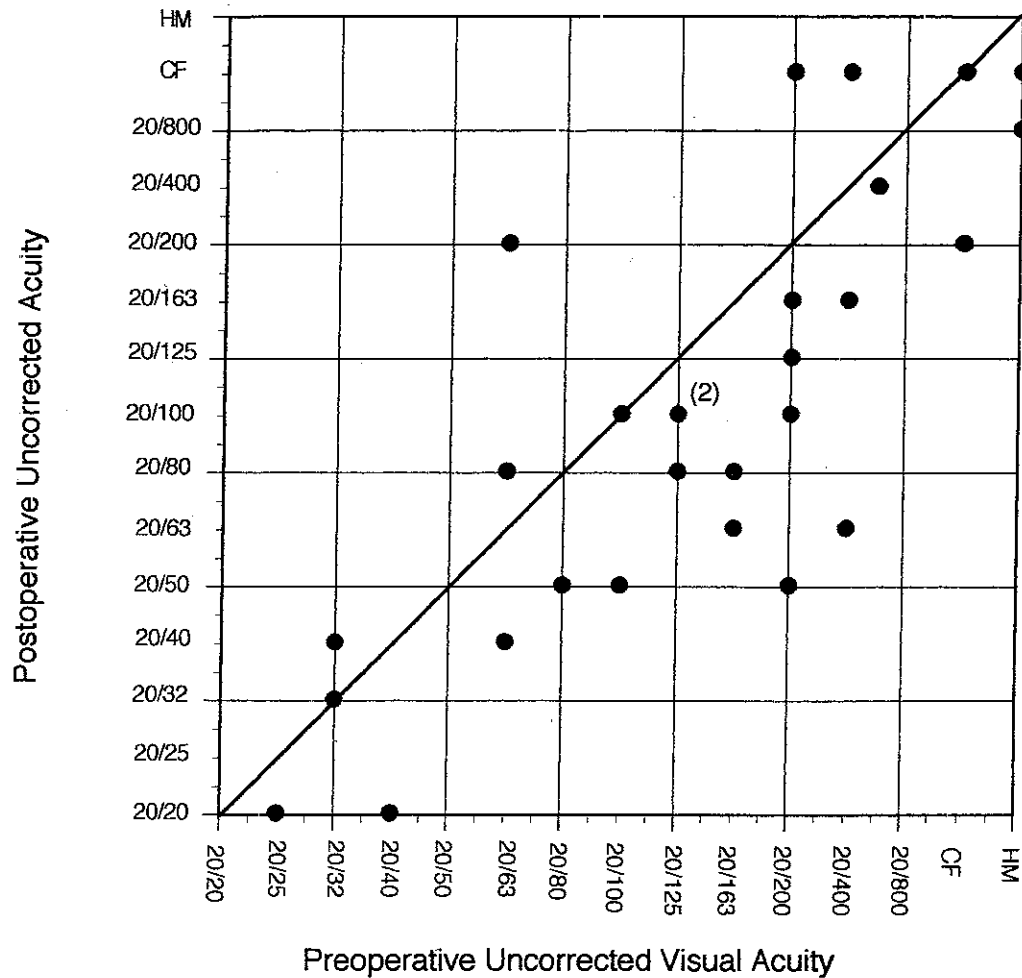


Figure 6. Scattergram shows preoperative versus postoperative, uncorrected visual acuity of individual patients. For points depicting more than one patient, the actual number is indicated above and to the right of the point.

Complications

Epithelialization. Epithelial healing occurred within 3 days in 19 eyes and between 3 days and 1 week in 6 eyes. One patient with Salzmann degeneration, one with a corneal scar and preoperative epitheliopathy, and one with contact lens-induced keratopathy required adjunctive use of a bandage soft contact lens and up to 1 month for complete re-epithelialization.

Stromal Haze/Scarring. A trace to mild reticular subepithelial stromal haze was found in the treated area site of most patients. None of the eyes had more than mild haze. The degree of haze or scar was not judged clinically significant in any of the patients.

Infection. There were no infections or recurrences of herpes simplex keratitis in this series.

Corneal Graft Reaction. One patient with recurrent lattice dystrophy in a corneal graft had a graft rejection after PTK, which resolved completely with topical corticosteroids.²¹

Subsequent Penetrating Keratoplasty. Two patients underwent subsequent corneal transplantation. Both patients initially had poor vision secondary to stromal scarring, one secondary to herpetic keratitis, and the other

secondary to trauma, and did not appreciate adequate improvement in visual acuity after PTK.

Discussion

With the recent approval of the excimer laser by the United States Food and Drug Administration for managing superficial corneal disorders, the technique of PTK has added a new tool to the surgical armamentarium of the corneal surgeon. However, whereas the technique of PRK is generally consistent among patients, a number of surgical strategies are available with the PTK procedure. The surgeon, therefore, must practice careful case selection, devise an appropriate surgical strategy tailored to the individual patient problem, and properly execute the procedure to optimize clinical outcome. In addition, side effects unique to PTK must be recognized because these differ from those of both PRK and mechanical superficial keratectomy techniques.

Early clinical results have shown PTK to be helpful in patients with superficial corneal scars, opacities, and irregularities.^{12 17 22-24} The therapeutic success of PTK relies on the ability of the laser to meticulously remove tissue

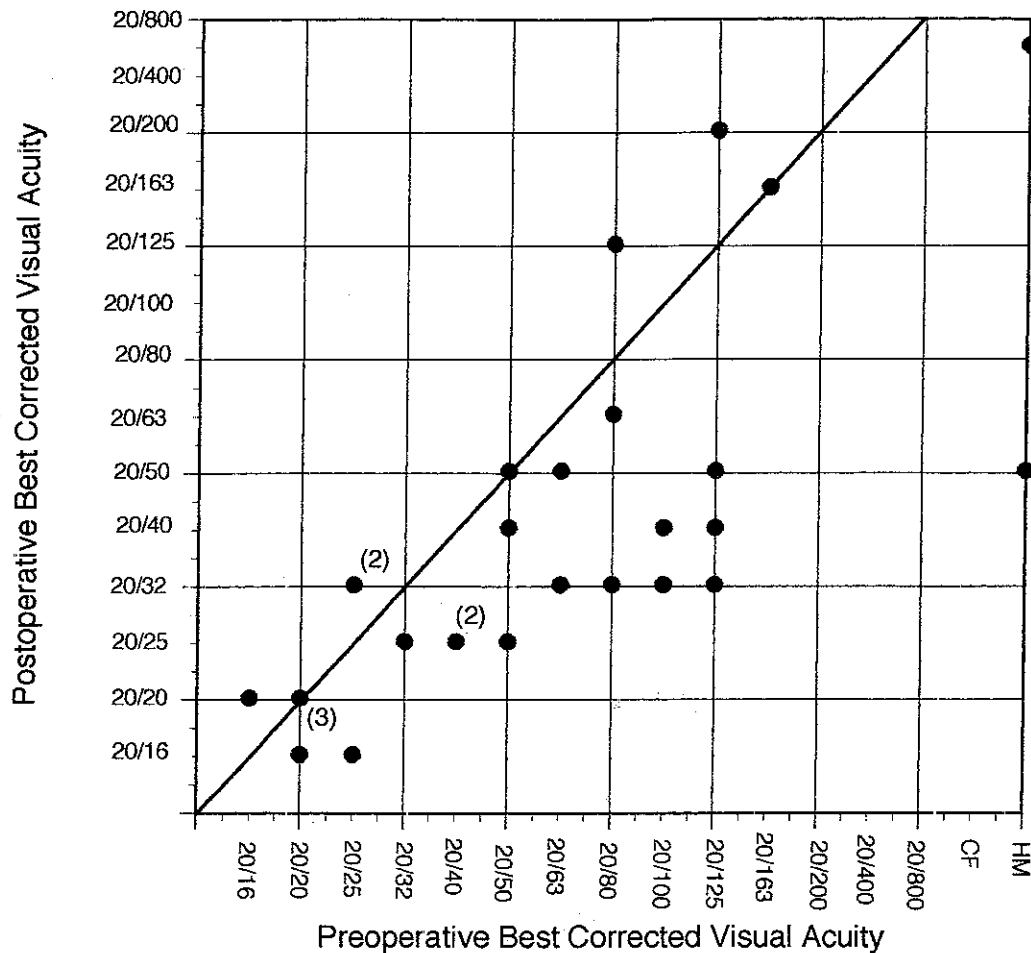


Figure 7. Scattergram shows preoperative versus postoperative best spectacle-corrected visual acuity of individual patients. For points depicting more than one patient, the actual number is indicated above and to the right of the point.

from the corneal surface and of the cornea to remain smooth without scarring to allow adequate epithelial regeneration and adherence to the new corneal surface.²⁵⁻³⁰ In this study, we performed PTK on 28 eyes: 21 showed improvement in visual acuity and 19 patients reported subjective improvement.

Case Selection. The efficacy of PTK seems to be related to several factors, including the nature of the preoperative corneal disorder and consequent treatment strategy, the patient's subjective complaint, and the preoperative refractive error.

Preoperatively, careful attention should be directed toward the specific patient complaints to better determine whether PTK may be expected to achieve the desired clinical goals. An in depth history and careful consideration of the individual patient's needs is, therefore, essential. For instance, one patient with Salzmann nodules and a visual acuity of 20/25 had recalcitrant monocular diplopia and photophobia. Focal PTK was rewarded by complete resolution of the patient's subjective complaints. A patient with poor vision showed, on examination, Reis-Buckers dystrophy, a refractive error of -7.0 D, and best-corrected visual acuity of 20/125. After PTK, her visual acuity improved to 20/50, with a -2.0-D correction. Thus, both best-corrected and uncorrected vision improved.

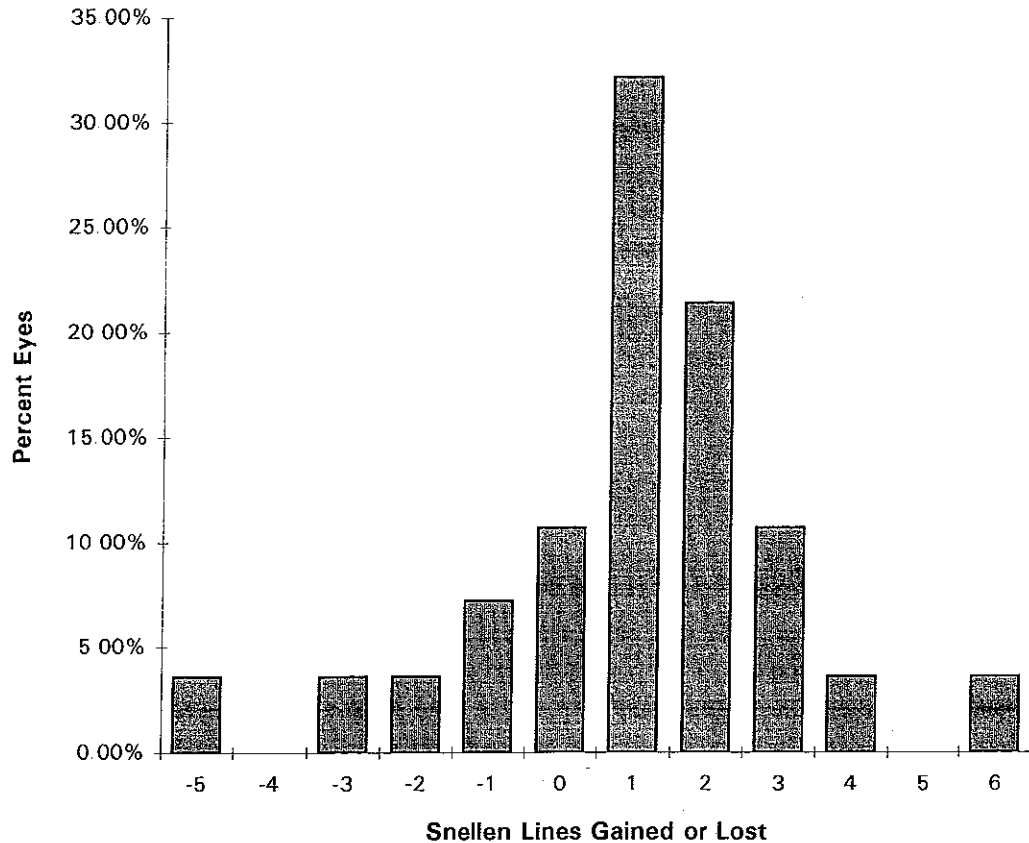
Results of examination of the patient's father, who also had Reis-Buckers dystrophy, showed similarly decreased best-corrected visual acuity but a preoperative refractive error of +5.0 D; excimer treatment was not undertaken. An understanding of surgical goals, both by the patient and the surgeon, is, therefore, important in ensuring satisfaction with the results of the procedure.

Treatment Strategies

General Large-area Phototherapeutic Keratectomy. In patients undergoing the general large-area PTK technique, the procedure appeared generally effective both in improving the patient's vision and decreasing subjective complaints, such as light sensitivity and ocular surface discomfort. These benefits appear to derive both from regularization of the corneal surface as well as restoration of corneal clarity. However, relatively large amounts of tissue might be removed with this technique; therefore, the surgeon and patient must be aware of refractive shifts that might arise from the procedure.²²

Such refractive shifts may be minimized and postoperative optical topography optimized by the PTK polishing technique as described. Careful surface smoothing must be done by applying methylcellulose. The thickness

Figure 8. Change in uncorrected visual acuity after phototherapeutic keratectomy



of the methylcellulose layer should be enough to smooth the valleys of the corneal surface, but not so much as to completely block the incoming laser beam. For example, a patient required 1095 pulses, which was done early in this series. Her second eye required approximately 600 pulses, which was completed approximately 6 months later. The postoperative pachymetry reading was similar after both procedures; therefore, this decreased laser treatment likely reflected an improvement in our surgical technique with more appropriate methylcellulose application in the second eye. An overly muted sound of the laser-tissue interaction may signal to the surgeon that too much methylcellulose has been applied. Collagen gels and other molding compounds hold promise for future use in the PTK procedure to provide a smoother postoperative corneal surface.⁷

Combined Mechanical Superficial Keratectomy and Phototherapeutic Keratectomy. Epithelium, stroma, calcium, fibrous scars, and dystrophic and degenerative materials may demonstrate differential ablation rates.^{13,14} Therefore, a point-and-shoot laser technique could result in an irregular surface because portions of the treated areas ablate more rapidly than others. Moreover, the resistance of some of these materials to laser ablation also makes a mechanical superficial keratectomy an important adjunct to PTK in patients with abundant abnormal material on the corneal surface. Calcific band keratopathy is exemplary of a corneal disorder requiring this technique. Moreover, a superficial fibrovascular pannus or pterygium

should be mechanically removed before PTK because, in addition to the large mass of tissue to be removed, intraoperative bleeding would block the incoming laser beam during the laser procedure.

Focal Smoothing. Focal nodules and excrescences may be smoothed with the excimer laser. For example, reports have suggested using focal PTK for apical nodules in patients with keratoconus to smooth the cornea and allow resumption of contact lens wear.¹⁸ Care should always be taken to minimize treatment to avoid creating craters in the place of the elevation. Mechanical superficial keratectomy may be a useful adjunct to focal PTK as well, for instance, in patients with Salzmann nodular degeneration.

Superficial Scar Removal. Although focal superficial scars within the corneal stroma may be removed with the excimer laser, their treatment exemplifies the importance of clearly defining therapeutic goals, identifying coincidental clinical effects, and adhering to meticulous technique. Although scars within the corneal stroma can be ablated with the excimer laser, perturbations in the postoperative corneal surface topography may require a rigid contact lens to achieve the best possible vision. In some patients, residual topographic irregularity actually may decrease uncorrected vision, whereas vision with a rigid contact lens may improve. In other patients, a perturbation in corneal topography may make the result unsatisfactory. One such patient in this study, although postoperative vision was im-

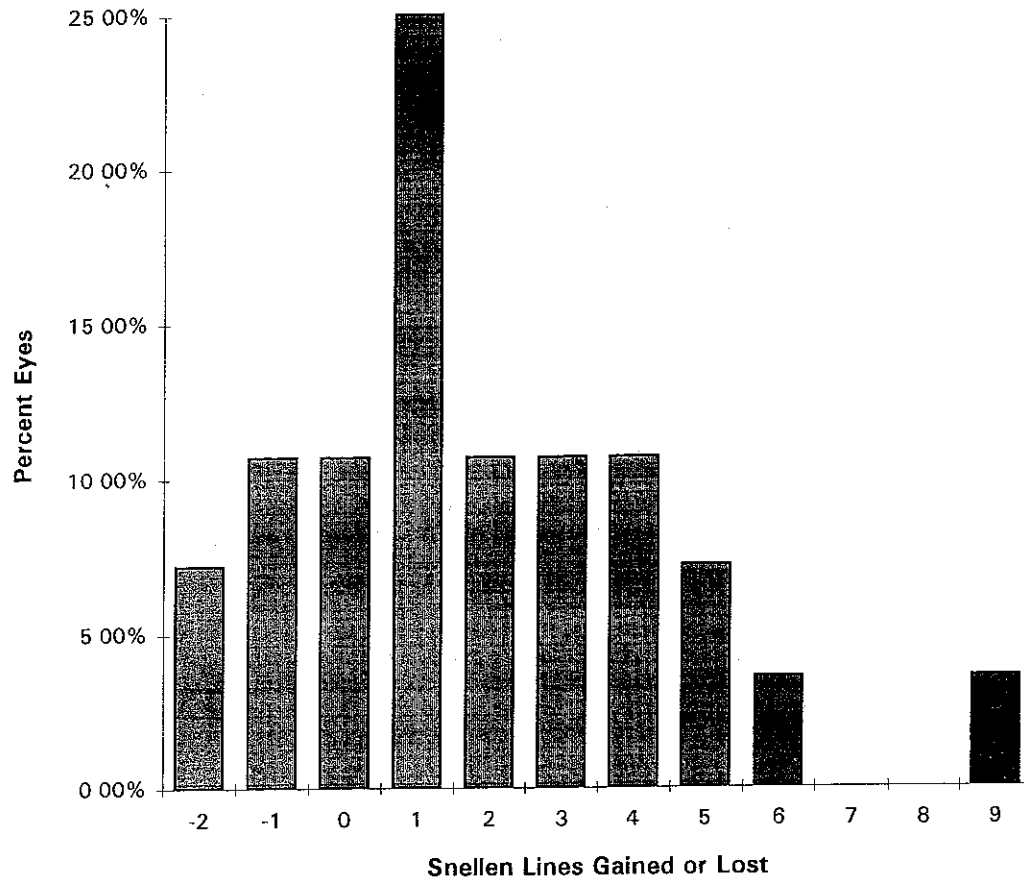


Figure 9. Change in best spectacle-corrected visual acuity after phototherapeutic keratectomy.

proved with a rigid contact lens, underwent subsequent penetrating keratoplasty.

In general, only superficial scars ($<100 \mu\text{m}$) should be treated. Optical or ultrasonic pachymetry may be helpful to judge the depth of the scar and overall corneal thickness.³¹ Thin corneas should not be treated because tissue removal will only further distort the corneal surface. When such scars are treated, ablation should be minimized and the treatment zone blended peripherally to decrease iatrogenic induction of irregular astigmatism.

Epithelial Basement Membrane Dystrophy and Recurrent Epithelial Erosion. This study included five patients with recurrent erosion syndrome and one with epithelial basement membrane dystrophy without an epitheliopathy. In the latter patient, treatment was performed to remove the abnormal basement membrane material that was causing both corneal opacification and surface irregularity with decreased vision.³² Recurrent erosions in four of the patients healed without subsequent episodes, whereas the erosions continued in one patient. Successful treatment of recurrent erosion syndrome is likely due to meticulous smoothing and cleaning of the subepithelial corneal surface, affording a substrate conducive to epithelial migration and adhesion.³³ Moreover, the minimal number of laser pulses necessary likely leads to little change in corneal topography or refractive error.³⁴

Minimizing Refractive Shifts and Topography Changes. In general, some degree of induced flattening

should be anticipated for most PTK procedures performed on the central cornea, whereas either central flattening or steepening may occur with more peripheral treatments such as smoothing of pterygium scars. The induced corneal flattening may be caused by (1) epithelial hyperplasia at the peripheral aspect of the ablation,²⁹ (2) attenuated fluence of the excimer laser beam at its peripheral aspect, or (3) the changing angle of incidence of the beam across the central corneal dome, resulting in a lower fluence peripherally with a decrease in effective tissue ablation and consequent corneal flattening³⁵ (Fig 10). McDonnell and Seiler³⁶ speculate, in addition, that some of the induced refractive change in Reis-Bucklers dystrophy simply may result from the excision of the abnormal subepithelial tissue by either a laser or mechanical superficial keratectomy technique. Steepening, in contrast, may occur when more tissue is ablated peripherally than centrally, thereby steepening the overall macroscopic optical contour of the cornea.

Refractive changes, therefore, should be anticipated when selecting patients for PTK.³⁷ Shifts away from emmetropia may be undesirable, leaving the patient unacceptably anisometropic or hyperopic. Refractive shifts may likely be minimized by blending the treatment zone using the techniques described and, importantly, by limiting the actual amount of tissue ablated. Deep stromal scars should be avoided; protruding surface excrescences are best. Treatment of the former often will result in per-

Table 2 Refractive Shift after Phototherapeutic Keratectomy

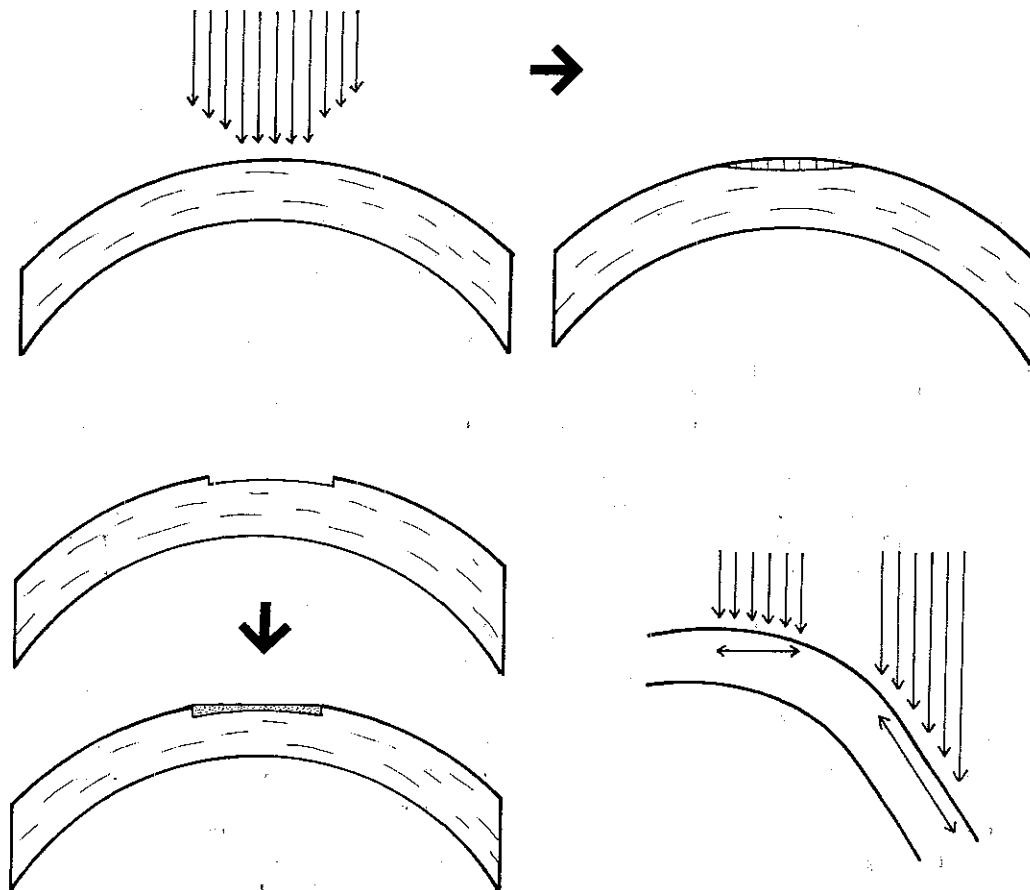
Technique	No. of Eyes	Mean Refractive Change	Mean No. of Laser Pulses	Mean Change in Corneal Thickness (μm)	No. of Eyes		
					+/-1.0 D of Preoperative Refraction	Hyperopic >1.00 D	Myopic >1.00 D
General large-area PTK	7	+2.9	643	46	2	4	1
PTK with superficial keratectomy	2	+4.1	498	110	1	1	0
Focal smoothing	6	-0.5	296	36	4	1	1
Scar removal	5	+2.7	524	69	1	4	0
EBMD/RES	5	+0.7	36	1	4	0	1
Total	25	+1.4	418	31	12	10	3

D = diopters; PTK = phototherapeutic keratectomy; EBMD/RES = epithelial basement membrane dystrophy/recurrent erosion syndrome

turbation of the corneal topography, whereas ablation of the latter will result in smoothing and regularization of the surface topography with reattainment of the normal corneal curvature. In addition, some surgeons advocate performing additional treatment at the end of the pro-

cedure using a small beam diameter to form a midperipheral annulus to steepen the overall corneal contour. Patients should be made aware of both the potential for refractive change and the alternatives available to correct vision postoperatively. For instance, removal of a central

Figure 10. Possible factors contributing to refractive shifts with phototherapeutic keratectomy are shown. Top, attenuation of laser fluence toward the periphery of the beam, resulting in relatively less tissue removal peripherally than centrally, with focal corneal flattening in the area of treatment. Notice that this flattening is exaggerated in the figure. Bottom left, relative epithelial hyperplasia at the peripheral aspect of the treatment zone leading to corneal surface flattening. Bottom right, the changing angle of incidence of the beam across the corneal dome results in a lower fluence peripherally, decreasing the effective tissue ablation and leading to flattening.



corneal scar may improve best spectacle- or rigid contact lens-corrected visual acuity³⁸ but actually decrease uncorrected vision because of either a refractive shift away from emmetropia or induced irregular astigmatism.

Complications. Postoperative complications were minimal in this study. However, unlike PRK, PTK is performed on diseased corneas. Therefore, complications associated with other corneal procedures must be anticipated with PTK.

Epithelialization. Epithelial healing was generally prompt, and complete healing occurred within 3 days in most patients. Three patients with preoperative corneal epitheliopathies required adjunctive treatment with lubrication and bandage soft contact lenses for up to 3 weeks after PTK with ultimate satisfactory re-epithelialization. In particular, patients with epithelial problems based on limbal stem cell deficiency may have difficulties with re-epithelialization after PTK. For instance, our one patient with a contact lens-related keratopathy required a bandage soft contact lens to promote complete healing and had a recurrence of an optically poor epithelial surface, despite initially successful PTK. Interventions to promote epithelialization such as the use of nonpreserved lubricants, bandage soft contact lenses, tarsorrhaphy, and management of blepharitis may all be helpful to promote prompt epithelialization and avoid persistent epithelial defects and sterile stromal ulceration after PTK.⁵

Corneal Haze and Scarring. There was no additional scarring compared with the preoperative level, and postoperative haze was graded as no more than mild in our patients. Minimizing inflammation with the careful use of corticosteroids and efforts to promote prompt epithelialization should help avoid excessive keratocyte activation and scar formation.

Microbial Keratitis. There was no occurrence of bacterial keratitis in this study. However, in such diseased corneas, especially with an epithelial defect, infection should be anticipated. Prophylactic antibiotic use, especially with an epithelial defect with bandage contact lens, may minimize the incidence of infection. Again, interventions to promote prompt epithelialization are likely important to avoid postoperative corneal infection.

Recurrent Herpes Simplex Keratitis. Reactivation of herpes has been reported after excimer laser keratectomy.²⁰ Similarly, PTK should not be performed on eyes with active herpes simplex virus, and the eye should remain quiescent for a specified amount of time before treatment. In addition, perioperative treatment with topical (e.g., trifluridine) and oral (e.g., acyclovir) antiviral agents may help minimize the incidence of recrudescence of herpetic disease.³⁹

Corneal Graft Rejection. One patient with recurrent lattice in a corneal graft had a graft rejection that resolved completely with corticosteroid treatment.²¹ Whether the graft rejection was precipitated by the laser treatment itself or by other aspects of the treatment (e.g., mechanical epithelial removal or subsequent corticosteroid use) is unclear. One additional patient with an immunologic corneal graft rejection has been reported to date in the literature.⁴⁰

Conclusions

Our study supports excimer laser PTK as a useful strategy for treating a number of corneal surface disorders. Careful case selection is of paramount importance. For instance, central corneal smoothing in a patient with myopia may be rewarded with both a clearer cornea and reduced refractive error, whereas central scar removal in a hyperopic patient, while clearing the cornea, may result in unacceptable hyperopia and perturbation of the corneal topography. Patients most suited to PTK appear to be those with surface excrescences where the procedure will both clear the cornea and improve the corneal surface optical contour. Both the surgeon and patient must understand the goals of the procedure, and a meticulously planned surgical strategy should be directed at the specific corneal disorder. Such preparation and execution will best lead to a satisfactory postoperative clinical result.

References

1. Hersh PS, Kenyon KR. Dystrophies, degenerations, and dysgeneses of the cornea. In: Jakobiec F, Albert D, eds. *Principles and Practice of Ophthalmology*. Philadelphia: WB Saunders, 1993;26-33.
2. Hersh PS. *Ophthalmic Surgical Procedures*. Boston: Little, Brown & Co, 1988;221-5.
3. Holladay JT, Prager TC. Mean visual acuity [letter]. *Am J Ophthalmol* 1991;111:372-4.
4. Hersh PS, Schwartz-Goldstein B. Summit PRK Topography Study Group. Corneal topography of phase III excimer laser photorefractive keratectomy: characterization and clinical effects. *Ophthalmology* 1995;102:963-78.
5. Kenyon KR, Tseng SCG. Limbal autograft transplantation for ocular surface disorders. *Ophthalmology* 1989;96:709-23.
6. Kornmehl EW, Steinert RF, Puliafito CA. A comparative study of masking fluids for excimer laser phototherapeutic keratectomy. *Arch Ophthalmol* 1991;109:860-3.
7. Englanoff JS, Kolahdouz-Isfahani AH, Moreira H, et al. In situ collagen gel mold as an aid in excimer laser superficial keratectomy. *Ophthalmology* 1992;99:1201-8.
8. Schwartz-Goldstein B, Hersh PS. Summit PRK Topography Study Group. Corneal topography of phase III excimer laser photorefractive keratectomy: optical zone centration analysis. *Ophthalmology* 1995;102:951-62.
9. Hersh PS, Spinak A, Garrana R, Mayers M. Excimer laser phototherapeutic keratectomy: strategies and results. *Refract Corneal Surg* 1993;9:S90-5.
10. Tuft S, Al-Dhahir R, Dyer P, Zehao Z. Characterization of the fluorescence spectra produced by excimer laser irradiation of the cornea. *Invest Ophthalmol Vis Sci* 1990;31:1512-8.
11. Gibralter R, Trokel SL. Correction of irregular astigmatism with the excimer laser. *Ophthalmology* 1994;101:1310-5.
12. Stark WJ, Chamon W. Clinical follow-up of 193 nm ArF excimer laser photokeratectomy. *Ophthalmology* 1992;99:805-12.
13. McDonnell JM, Garbus JJ, McDonnell PJ. Unsuccessful excimer laser phototherapeutic keratectomy. *Arch Ophthalmol* 1992;110:977-9.
14. Binder PS, Anderson JA, Rock ME, Vrabcic M. Human excimer laser keratectomy. Clinical and histopathologic correlations. *Ophthalmology* 1994;101:979-89.

15. Wood IO, Fleming JC, Dotson RS, Cotten MS. Treatment of Reis-Bucklers' corneal dystrophy by removal of subepithelial fibrous tissue. *Am J Ophthalmol* 1978;85:360-2.
16. Hersh PS, Kenyon KR. Anterior segment reconstruction following ocular trauma. In: Shingleton BJ, Hersh PS, Kenyon KR, eds *Eye Trauma*. St Louis: Mosby-YearBook, 1991;176.
17. Steinert RF, Puliafito CA. Excimer laser phototherapeutic keratectomy for a corneal nodule. *Refract Corneal Surg* 1990;6:352.
18. Ward MA, Artunduaga G, Thompson KP, et al. Phototherapeutic keratectomy for the treatment of nodular subepithelial corneal scars in patients with keratoconus who are contact lens intolerant. *CLAO J* 1995;21:130-2.
19. Kenyon KR, Wagoner MD. Conjunctival and corneal injuries. In: Shingleton BJ, Hersh PS, Kenyon KR, eds *Eye Trauma*. St Louis: Mosby-YearBook, 1991:70-1.
20. Vrabc MP, Durrie DS, Chase DS. Recurrence of herpes simplex after excimer laser keratectomy. *Am J Ophthalmol* 1992;114:96-7.
21. Hersh PS, Jordan AJ, Mayers M. Corneal graft rejection episode after excimer laser phototherapeutic keratectomy. *Arch Ophthalmol* 1993;111:735-6.
22. Sher NA, Bowers RA, Zabel RW, et al. Clinical use of the 193-nm excimer laser in the treatment of corneal scars. *Arch Ophthalmol* 1991;109:491-8.
23. Rapuano CJ, Laibson PR. Excimer laser phototherapeutic keratectomy for anterior corneal pathology. *CLAO J* 1994;20:253-7.
24. Tuunanen TH, Iervo IM. Excimer laser phototherapeutic keratectomy for corneal diseases: a follow-up study. *CLAO J* 1995;21:67-72.
25. Trokel SI, Srinivasan R, Braren R. Excimer laser surgery of the cornea. *Am J Ophthalmol* 1983;96:710-5.
26. L'Esperance FA, Taylor DM, Warner JW. Human excimer laser keratectomy: short term histopathology. *J Refract Surg* 1988;4:118-24.
27. Marshall J, Trokel SL, Rothery S, Krueger RR. Long-term healing of the central cornea after photorefractive keratectomy using an excimer laser. *Ophthalmology* 1988;95:1411-21.
28. Goodman GL, Trokel SL, Stark WJ, et al. Corneal healing following laser refractive keratectomy. *Arch Ophthalmol* 1989;107:1799-803.
29. Wu WCS, Stark WJ, Green WR. Corneal wound healing after 193-mm excimer laser keratectomy. *Arch Ophthalmol* 1991;109:1426-32.
30. Gartry D, Muir MK, Marshall J. Excimer laser treatment of corneal surface pathology; a laboratory and clinical study. *Br J Ophthalmol* 1991;75:258-68.
31. Reinstein DZ, Aslanides IM, Silverman RH, et al. High frequency ultrasound corneal pachymetry in the assessment of corneal scars for therapeutic planning. *CLAO J* 1994;20:198-203.
32. Kenyon KR, Hersh PS, Starck T, Fogle JA. Corneal dysgeneses, dystrophies and degenerations. In: Tasman W, ed *Duane's Clinical Ophthalmology*. Philadelphia: JB Lippincott Co, 1992;1-14.
33. Dausch D, Landes M, Klein R, Schroder E. Phototherapeutic keratectomy in recurrent corneal epithelial erosion. *J Refract Corneal Surg* 1993;9:419-24.
34. John ME, Van Der Karr MA, Noblitt RL, Boleyn KL. Excimer laser phototherapeutic keratectomy for treatment of recurrent corneal erosion. *J Cataract Refract Surg* 1994;20:179-82.
35. Blaker JW, Hersh PS. Theoretical and clinical effect of corneal curvature on excimer laser photorefractive keratectomy. *Refract Corneal Surg* 1994;10:571-4.
36. McDonnell P, Seiler T. Phototherapeutic keratectomy with excimer laser for Reis-Bucklers' corneal dystrophy. *J Refract Corneal Surg* 1992;8:306-10.
37. Campos M, Nielsen S, Szerenyi K, et al. Clinical follow-up of phototherapeutic keratectomy for the treatment of corneal opacities. *Am J Ophthalmol* 1993;115:433-40.
38. Eggink FAGJ, Houdijn Beekhuis W. Granular dystrophy of the cornea. Contact lens fitting after phototherapeutic keratectomy. *Cornea* 1995;14:217-22.
39. Vrabc MP, Anderson JA, Rock ME, et al. Electron microscopic findings in a cornea with recurrence of herpes simplex keratitis after excimer laser phototherapeutic keratectomy. *CLAO J* 1994;20:41-4.
40. Epstein RJ, Robin JB. Corneal graft rejection episode after excimer laser phototherapeutic keratectomy [letter]. *Arch Ophthalmol* 1994;112:157.