

CORNEA/EXTERNAL DISEASE

OCULAR SURGERY NEWS U.S. EDITION March 25, 2011

Surgical Maneuvers

Microwave thermokeratoplasty with corneal collagen cross-linking used to treat keratoconus

Studies of the combined procedure are currently under way in Europe and Turkey.

by Peter S. Hersh, MD

Keratoconus is an ectatic corneal disease that is usually bilateral, noninflammatory but may be subinflammatory, and often progressive in its course. Paraxial corneal stromal thinning and weakening, along with often associated corneal scarring, cause corneal surface distortion, irregular astigmatism, myopia and degradation of the quality of vision. The zone of corneal ectasia usually, but not exclusively, involves the axial and inferonasal cornea.

The National Eye Institute reports that keratoconus is the most common corneal dystrophy in the U.S., with an incidence of about one in 2,000. This incidence appears to be increasing as newer technological advances allow us to detect early keratoconus. In addition to rigid contact lens wear as a risk factor, one has to look for other associated conditions such as ocular allergies and vigorous eye rubbing. The recently expanded corneal treatment modalities include contact lens wear, Intacs (Addition Technology), collagen cross-linking, penetrating keratoplasty (manual and IntraLase-enabled), deep anterior lamellar keratoplasty and total anterior lamellar keratoplasty. Further advancements in surgical technique include the use of microwave thermokeratoplasty combined with collagen cross-linking for keratoconus and ectasia. The goal of this novel treatment approach is to both flatten the cornea and stabilize the keratoconus. These procedures are not approved by the U.S. Food and Drug Administration and are in the early stages of clinical evaluation outside the U.S.

In this column, Dr. Hersh describes the surgical technique of combined microwave thermokeratoplasty with collagen cross-linking for keratoconus and corneal ectasia.

Thomas John, MD

OSN Surgical Maneuvers Editor

The procedure is centered on the corneal apex. The surgeon marks the apex, as noted by the first Purkinje image, with a Sinskey hook and gentian violet. Next, the surgeon applies the handheld targeting stage to the eye (Figure 1). This is similar to the application of a microkeratome suction ring. Suction is applied. A centration guide is placed (Figure 2). The applicator ring is then centered precisely over the centration mark using X-Y translation dials on the instrument, and the targeting stage is locked into position (Figure 3). The microwave handpiece is inserted into the targeting stage and engaged (Figure 4).

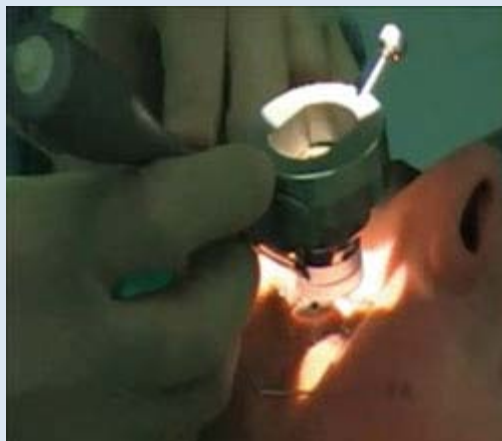

Figure 1. Targeting stage is placed on the eye, and suction is applied.

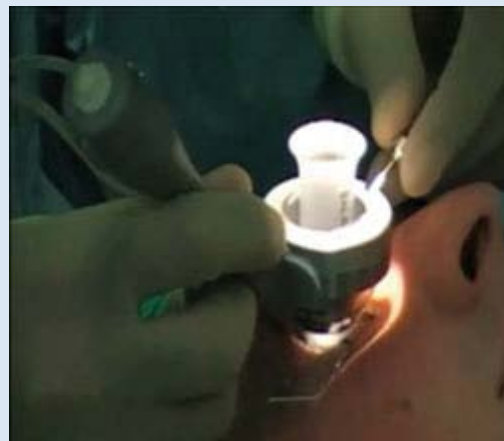

Figure 2. Centration guide placed.

Images: Hersh PS

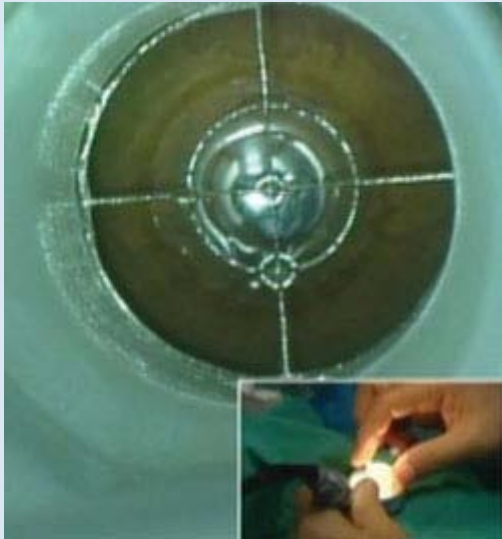

Figure 3. Applicator ring is centered over corneal apex mark using X-Y translation dials.

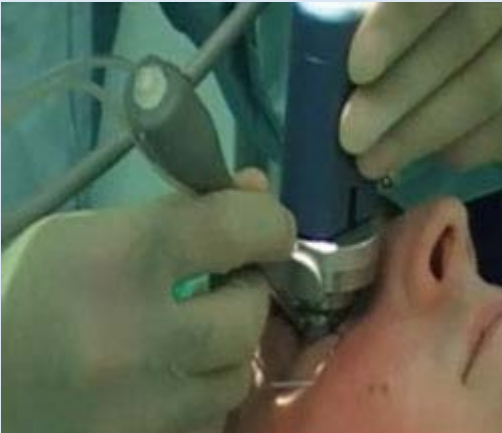

Figure 4. Microwave handpiece is positioned and engaged into targeting stage.

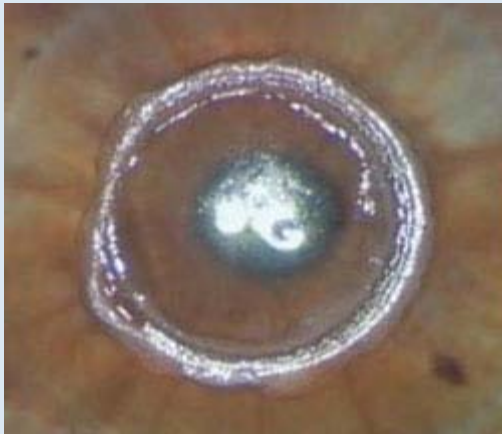


Figure 5. Annular epithelial defect immediately after procedure.

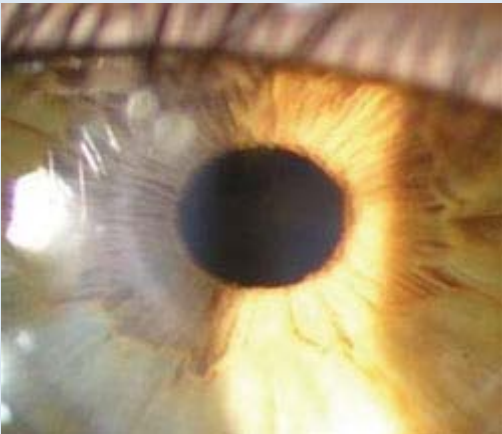


Figure 6. Week 1 postoperative appearance.

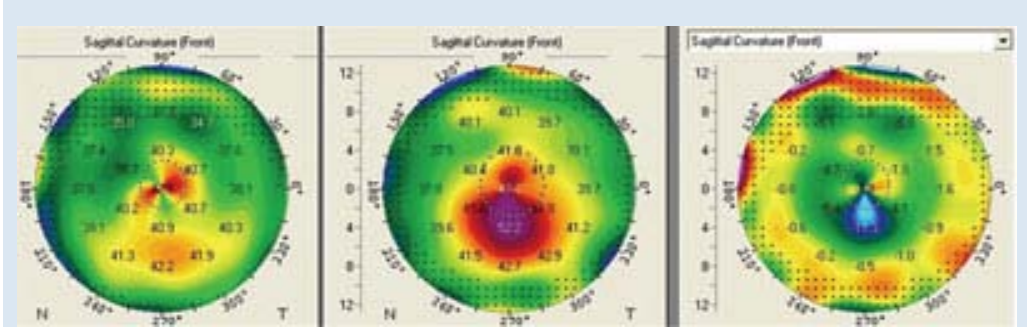


Figure 7. Representative preoperative and 3 month postoperative topography with difference map.

The interface on the handpiece then cools the cornea to a preset temperature. Cooling sets standard baseline parameters and helps to make the procedure reproducible between patients. Next, the circular electrode applies the microwave treatment energy. The electrode is computer-controlled and automatically delivers the treatment to the

desired specifications. Energy is applied in a ring that is approximately 4 mm in diameter and between 200 µm and 500 µm wide; the depth of the treatment is about 150 µm. The dimensions of the applicator electrode determine the degree of correction and the energy delivered. The actual application of microwave energy takes less than a second, after which suction is disengaged and the instrument is removed.

Immediately postoperatively, patients have a small annular defect in the epithelium overlying the treatment ring (Figure 5). The surgeon may debride this area and apply a bandage soft contact lens for comfort. The epithelium typically heals within 24 hours (Figure 6). Antibiotic drops are used to prevent infection.

In the subsequent cross-linking procedure, which may be performed immediately after Keraflex (Avedro) or at a later date, riboflavin 0.1% drops are administered after the corneal epithelium is debrided. UV cross-linking is accomplished at a wavelength of 365 nm and a power of 3 mW/cm² for 30 minutes, or for 3 minutes using the new Keraflex KXL system. This new system operates at a power of 30 mW/cm² and decreases UV application time to 3 minutes. An ultraviolet-blocking mask is used to protect the peripheral cornea and limbus, and the riboflavin is flushed from the surface with balanced salt solution before UV exposure to ensure uniform cross-linking.

Clinical studies of the Keraflex KXL procedure are currently ongoing in Europe and Turkey. Early results appear promising. In a series of patients who were treated in Istanbul by Prof. Faruk Yilmaz and followed for 3 months, investigators found that Keraflex combined with collagen cross-linking achieved an average of 6 D of corneal flattening and a mean change in manifest refraction spherical equivalent of 4.39 D. Regularity of the corneal topography also appeared improved (Figure 7). Longer-term follow-up studies to determine stability of the procedure are under way.

There are a few risks to consider in Keraflex and cross-linking. Although the epithelial defect is small, care should be taken with patients who are at high risk of infection or delayed epithelial healing. Also, although the goal of the Keraflex procedure is to improve corneal optics, any change in corneal topography presents a risk of optical side effects such as glare, halo or diplopia. In addition, patients who have an overly thin cornea in the mid-peripheral area to be treated and patients with central corneal scars are not candidates for the procedure.

Keraflex KXL has the potential to decrease the number of corneal transplants performed in patients with keratoconus who otherwise have no other alternative for treatment. While the Keraflex procedure is currently being evaluated for the treatment of keratoconus, studies looking at the treatment for low degrees of myopia have started.

References:

- Hersh PS, Greenstein SA, Fry KL. Corneal collagen crosslinking for keratoconus and corneal ectasia: One year results. *J Cat Refract Surg.* 2011;37(1):149-160.
- John T, ed. *Lamellar Corneal Surgery.* New York: McGraw-Hill Companies; 2008.
- John T, ed. *The Chicago Eye and Emergency Manual.* Panama City, Panama: Jaypee-Highlights Medical Publishers Inc.; 2011:35-90.
- O'Brat DP, Chan E, Samaras K, Patel P, Shah SP. A randomised, prospective study to investigate the efficacy of riboflavin/ultraviolet A (370 nm) corneal collagen cross-linkage to halt the progression of keratoconus [published online ahead of print Feb. 24, 2011]. *Br J Ophthalmol.* doi:10.1136/bjo.2010.196493.

-
- Thomas John, MD, is a clinical associate professor at Loyola University at Chicago and is in private practice in Oak Brook, Tinley Park and Oak Lawn, Ill. He can be reached at 708-429-2223; fax: 708-429-2226; e-mail: tjcornea@gmail.com.
 - Peter S. Hersh, MD, FACS, is a clinical professor at UMDNJ-New Jersey Medical School and is in private practice at The Cornea and Laser Eye Institute – Hersh Vision Group, CLEI Center for Keratoconus, 300 Frank W. Burr Blvd., Suite 71, Teaneck, NJ 07666; 201-883-0505; fax: 201-692-9646; e-mail: phersh@vision-institute.com.
 - Disclosures: Dr. John has no direct financial interests in the products or companies mentioned in this article. Dr. Hersh is medical monitor to Avedro Inc.