

Conductive Keratoplasty to Treat Complications of LASIK and Photorefractive Keratectomy

Peter S. Hersh, MD,^{1,2} Kristen L. Fry, OD,^{1,2} Ravindra Chandrashekhar, MD,¹ Desipina S. Fikaris, BS¹

Purpose: To assess the outcomes of conductive keratoplasty (CK) for patients with complications related to LASIK or photorefractive keratectomy (PRK).

Design: Retrospective, noncomparative, interventional case series.

Participants: Sixteen eyes of 15 patients were treated using CK after complications of initial LASIK or PRK surgeries. Five cases are described in detail.

Intervention: Rehabilitative CK was performed.

Main Outcome Measures: Uncorrected visual acuity (UCVA) and best spectacle-corrected visual acuity (BSCVA), refractive error, keratometry, topography analysis, and a subjective assessment of visual quality.

Results: After CK treatment, there was a mean improvement in UCVA of 2 lines; 1 eye lost >1 line of UCVA. Best-corrected visual acuity improved or remained the same in 12 of 15 eyes; no eyes lost >1 line of BSCVA. There was a mean reduction in astigmatism of 54%. Videokeratography generally demonstrated improved quality of the corneal optical surface, and patients reported a reduction in optical symptoms such as glare and halo.

Conclusions: Conductive keratoplasty may give improved corneal optics and vision in patients with complications of LASIK or PRK. This application of CK offers an alternative in cases in which further flap manipulation or laser treatments are contraindicated. *Ophthalmology* 2005;112:1941-1947 © 2005 by the American Academy of Ophthalmology.

Complication rates for LASIK and photorefractive keratectomy (PRK) have been variously reported, ranging from 0.7% to 11.8%.¹⁻⁹ Such rates vary widely and may not be comparable because some studies include cases of optical complications such as night glare or halo, whereas others include only frank surgical or postsurgical complications such as flap buttonhole or infection. Patients with significant LASIK and PRK complications often face a lengthy multi-step recovery process. For example, techniques such as flap lifting, smoothing, suturing, and phototherapeutic keratectomy (PTK) may be employed, and secondary LASIK and PRK refractive corrections may be necessary.^{2,7,10-12} In some cases, however, further laser correction or flap ma-

nipulation is undesirable. For a subset of these, we have found that conductive keratoplasty (CK) may afford a useful tool for corneal rehabilitation.

The CK procedure uses radiofrequency energy to reshape the cornea biomechanically via thermal collagen shrinkage.¹³⁻¹⁶ Using a circumferential spot pattern applied via a 450- μ m probe, CK has been successful in the treatment of mild to moderate spherical hyperopia in previously untreated eyes.¹⁷⁻¹⁹ A collagen shrinkage strategy also could be useful in complicated cases of LASIK and PRK, particularly to treat hyperopia, astigmatism, or irregular astigmatism when further laser or flap manipulation is contraindicated. Therefore, in this report we present a case series in which CK was performed in an effort to rehabilitate the cornea after complications of excimer laser surgery.

Originally received: November 19, 2004.

Accepted: May 16, 2005

Manuscript no 2004-323.

¹ Cornea and Laser Eye Institute—Hersh Vision Group, Teaneck, New Jersey.

² Institute of Ophthalmology and Visual Science, University of Medicine & Dentistry of New Jersey—New Jersey Medical School, Newark, New Jersey.

Dr Hersh is a member of the medical advisory board of Refractive Inc., Irvine, California. No other author has a financial or proprietary interest in any devices or methods discussed.

This study was supported in part by an unrestricted grant to the Department of Ophthalmology of New Jersey Medical School from Research to Prevent Blindness, Inc., New York, New York.

Reprint requests to Peter S. Hersh, MD, Cornea and Laser Eye Institute—Hersh Vision Group, 300 Frank W. Burr Boulevard, Teaneck, NJ 07666. E-mail: phersh@vision-institute.com.

Patients and Methods

Study Population

Patients who had LASIK and PRK complications and suffered a contraindication to further laser surgery were included in this case series. Patients who required routine refractive enhancement surgery were not included.

Twenty-five CK procedures were performed on 16 eyes of 15 patients. One patient was treated bilaterally. Six eyes required only 1 CK procedure, 6 eyes had 2 procedures each, 1 eye had 3, and 1 eye had 4. Thirteen patients were male, and 2 were female. The mean age was 50.6 years (± 12.0 ; range, 23–75). The number of treatment spots ranged from 4 to 26, with a mean of 15. Mean

follow-up was 143.1 days from last CK treatment (± 107.1 ; range, 7–361).

Conductive Keratoplasty Procedure

Full informed consent was given, and the patients were advised that CK was being performed as an off-label non-Food and Drug Administration approved procedure. Before each operating session, the CK instrument was calibrated per the manufacturer's recommended procedure. The axis of treatment for astigmatism corrections was marked at the slit lamp with a tissue marking pen.

After the patient was supine on the operating table, the operative field was prepared in a sterile fashion with povidone iodine. A patch was taped over the nontreated eye to facilitate coaxial fixation by the patient. Tetracaine drops were instilled 3 times to achieve topical anesthesia. The CK lid speculum was placed. The patient was asked to look at a coaxial fixation target, and a CK marking instrument coated with gentian violet was placed centered on the pupil and properly aligned with regard to astigmatism axis. This instrument has a 7.0-mm central ring and 8 radial posts extending to the 6.0- and 8.0-mm optical zones to guide spot placement. Cellulose sponges were used to remove any residual fluid from the surface.

Conductive keratoplasty spots were applied using the gentian violet template as a guide. Care was taken to assure that the probe was placed perpendicular to the cornea. Enough force was applied to the tip to assure maximum penetration depth up to the stop. After each ring was applied, the probe tip was inspected under the microscope and any epithelial debris carefully cleaned with a cellulose sponge.

At the end of the procedure, prednisolone acetate 1% and an antibiotic drop were applied. The patient continued these drops 4 times daily for 1 week.

Nomogram

Using the standard CK nomogram, a single ring of 8 spots at a 7-mm diameter gives an expected correction of +0.75 to +0.875 diopters (D). Adding a second ring at a 6-mm diameter gives a correction of +1.0 to +1.875 D. Adding a third ring at 8 mm gives +1.75 to +2.25 D. Finally, adding 8 spots at the 7-mm diameter gives an expected correction of +2.375 to +3.00 D. Our clinical experience suggested, however, that a greater effect is achieved in corneas having undergone previous myopic LASIK and PRK, ostensibly secondary to central corneal thinning. Thus, in general, treatments were planned conservatively with the anticipation that double the clinical effect would be achieved using the standard nomogram. Intraoperative keratometry measurements then guided further spot placement. For astigmatism treatments, our general goal in cases done later in our series was to treat 150% to 200% of the cylinder on keratometry, because our experience in earlier cases suggested some regression in the astigmatism correcting effect over time. For instance, if the cornea preoperatively was 3 D steep at 90°, we would aim for an immediate postoperative change to 1.5 to 3.0 D steep at 180°. In general, CK application was started with 2 spots straddling the flat axis at an optical zone of 9 mm. Intraoperative keratometry and topography analysis then were used to guide further spot placement, including both additional spots at the same optical zone or at a smaller optical zone if more effect was necessary.

Data Acquisition and Analysis

Distance (6.0 m) UCVA was measured under controlled lighting conditions using a back-illuminated Early Treatment Diabetic Retinopathy Study chart (Lighthouse for the Blind, New York, NY).

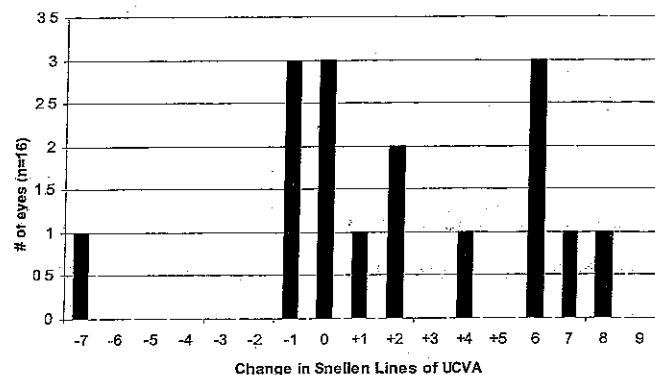


Figure 1. Change in uncorrected visual acuity (UCVA) after conductive keratoplasty.

At near (0.40 m), visual acuity (VA) was obtained using a Jaeger VA chart. All VA measurements were reported on the logarithm of the minimum angle of resolution (logMAR) scale, and mean VAs were derived using logMAR acuities. Keratometry was performed with a manual keratometer (Bausch & Lomb, Rochester, NY).

Results

Preoperative Data

In all patients studied, the mean distance uncorrected VA (UCVA) was 20/64, and near UCVA was 20/23. Best spectacle-corrected VA (BSCVA) was 20/23. Mean manifest refraction spherical equivalent (SE) was +1.09 D (± 1.24 ; range, -1.63 to +3.75). Mean refractive cylinder was 1.92 D (± 1.71 ; range, 0–5.5).

Postoperative Data

Uncorrected Visual Acuity. Mean distance UCVA improved to 20/37, an average of 2 lines. Nine eyes showed improved UCVA, 3 eyes had no change, and 4 eyes worsened (Fig 1). One eye had a significant loss of UCVA. That patient was overcorrected with a postoperative refraction of $-1.0/-2.0 \times 120^\circ$ and a consequent decrease in UCVA from 20/30 to 20/200. Postoperative mean near UCVA was 20/47.

Best Spectacle-Corrected Visual Acuity. Mean BSCVA after CK was 20/24. The mean change in lines of BSCVA was -0.13. One patient showed 1 line of improved BSCVA, 11 eyes had no change, and 3 eyes worsened by 1 line (Fig 2).

Manifest Refraction Spherical Equivalent and Refractive Cylinder. Manifest refraction SE improved to -0.15 D (± 0.72 ; range, -2.0 to +1.13). Mean cylinder decreased 54% to 0.88 D (± 0.78 ; range, 0–2.75). The mean change in cylinder was a reduction of 1.0 D (Fig 3).

Case Reports

Figure 4 summarizes the preoperative data, CK surgical strategy, and postoperative outcomes of the individual reported cases.

Case 1 (Free LASIK Flap; Hyperopic Astigmatism)

A 54-year-old woman was seen in consultation after experiencing a free flap during the LASIK procedure. Despite the free flap, laser

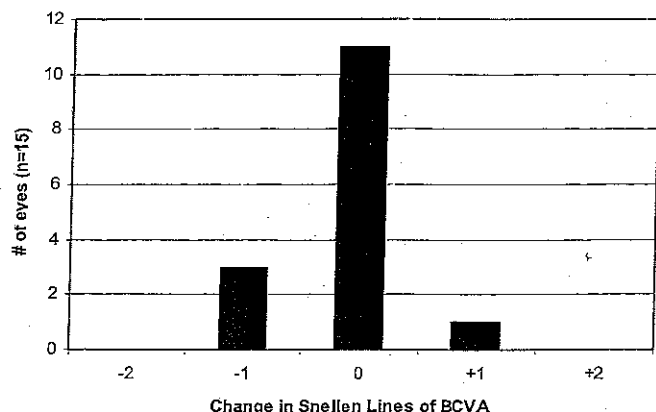


Figure 2. Change in best spectacle-corrected visual acuity (BCVA) after conductive keratoplasty

refractive correction was administered. Reportedly, the lamellar flap was found to be dislocated and was repositioned the day after initial treatment. Subsequently, she underwent a second flap repositioning with removal of epithelial ingrowth and flap suturing.¹²

Six months later, UCVA was 20/50. Flap sutures previously had been removed. Manifest refraction of $+3.75/-5.50 \times 150^\circ$ yielded 20/30 VA. Corneal pachymetry was 509 μm . Slit-lamp examination revealed a clear cornea with a smooth flap. Because further flap manipulation and laser treatment were considered to be contraindicated, the patient underwent CK for treatment of residual hyperopic astigmatism. Six CK spots were placed at a 9-mm optic zone, straddling the flat 152.5° meridian (3 superiorly, 3 inferiorly) (Fig 5). Surgery was uncomplicated. Intraoperative keratometry measurement was $47.50/46.00 \times 155^\circ$. One week after CK, UCVA in the left eye was 20/20, with manifest refraction of $+0.25/-1.25 \times 140^\circ$. Three months postoperatively, the patient was retreated using CK for residual hyperopic astigmatism of $+1.25/-1.75 \times 150^\circ$. Four additional CK spots were positioned in the 8-mm optic zone, straddling the 150° meridian (2 superior, 2 inferior). Intraoperative keratometry measurement was $49.00/45.50 \times 75^\circ$. One day after the CK retreatment, UCVA was 20/20 and keratometry was $47.50/47.00 \times 180^\circ$. One month after retreatment, VA remained good, with UCVA of 20/25 and manifest refraction of $\text{plano}/-0.50 \times 135^\circ$. One year later, manifest refraction was $+0.50/-1.00 \times 150^\circ$, with 20/30 UCVA. Topographic analysis showed a much improved cornea contour (corneal uniformity index, 70%, vs. 30% preoperatively; Holladay Diagnostic Summary, EyeSys, Houston, TX) and reduced astigmatism.

Case 2 (Flap Striae; Mixed Astigmatism)

A 59-year-old male presented with complaints of glare and halo in his right eye after bilateral LASIK surgery 1 year earlier. Subsequently, he underwent a PTK procedure for treatment of map-dot-fingerprint dystrophy and flap striae.¹⁰

Two months after PTK, UCVA was 20/25 and manifest refraction was $+1.00/-1.50 \times 135^\circ$, giving 20/20. Keratometry measurement was $40.50/39.25 \times 150^\circ$, with regular mires. The map-dot-fingerprint dystrophy and flap striae were markedly reduced. Because further flap manipulation was considered inadvisable because of previous striae and epithelial problems, the patient underwent CK for residual hyperopic astigmatism. Five spots were delivered (3 spots superiorly, 2 spots inferiorly) straddling the flat 125° meridian at an optical zone of 8 mm. Intraoperative keratometry was $42.50/40.00 \times 15^\circ$.

Visual acuity 1 day after CK was 20/20, and keratometry

measurement was $41.00/39.25 \times 180^\circ$. At 2 months postoperatively, VA was 20/25, improving to 20/20 with manifest refraction of $+0.75/-0.50 \times 130^\circ$. Repeated refractive and keratometric measurements over the next 6 months remained consistent. Therefore, the patient underwent a repeat CK treatment for the residual hyperopia. Eight additional CK spots were placed at the 8-mm optic zone diameter. Intraoperative keratometry was $42.00/41.50 \times 170^\circ$. One day after retreatment, vision was 20/20. At 1 month, UCVA remained 20/20, manifest refraction was $\text{plano}/-0.75 \times 155^\circ$, and keratometry was $42.00/41.25 \times 175^\circ$. Subjective glare and halo symptoms were resolved.

Case 3 (Flap Striae; Hyperopia)

A 43-year-old male underwent LASIK in the right eye, with an attempted correction of $-3.00/-1.00 \times 112.5^\circ$. After a second retreatment for residual refractive error, flap striae were noted. Therefore, the patient underwent flap repositioning and smoothing. Two months later, the flap again was relifted, smoothed using adjunctive hypotonic saline, and repositioned using 6 radial sutures for treatment of residual striae. Three months later, UCVA was 20/200, improving to 20/20 with manifest refraction of $+1.75 \text{ D}$. Keratometry was $38.75/38.50 \times 90^\circ$.

Because further flap manipulation was considered inadvisable secondary to resolution of flap striae and extensive previous manipulation, CK was performed using 8 spots at a 7-mm optic zone diameter. An additional spot was placed at 8 mm along the 90° meridian based on intraoperative topographic and keratometric findings. One day after CK, UCVA was 20/80 and the keratometry measurement was $42.25/40.00 \times 80^\circ$. Two months later, UCVA had improved to 20/40. Manifest refraction was $+0.50/-1.00 \times 65^\circ$, giving 20/30 VA. Keratometry was $40.00/39.50 \times 85^\circ$.

Case 4 (Thin Flap; Irregular Hyperopic Astigmatism)

A 23-year-old male was seen in consultation after LASIK for myopia during which a thin flap had occurred. Notwithstanding, the laser treatment was performed and the patient subsequently underwent a retreatment for residual refractive error.

The patient presented with a complaint of visual distortion. Uncorrected distance VA was 20/100, and near UCVA was 20/50. Manifest refraction of $+1.75/-6.00 \times 155^\circ$ gave VA of 20/25.

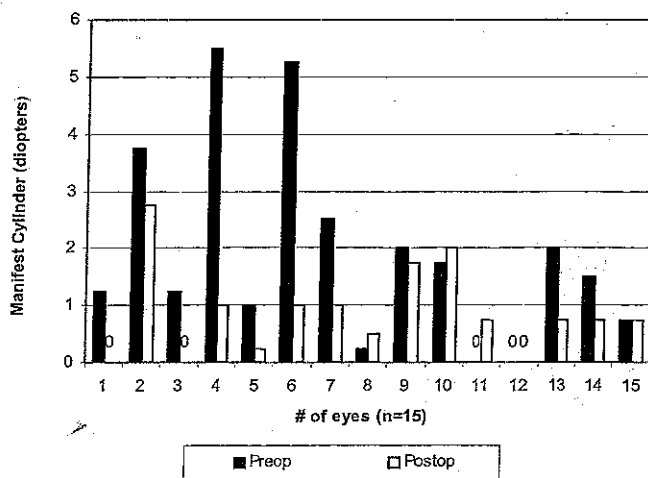


Figure 3. Manifest cylinder magnitude in individual eyes before (preop) and after (postop) conductive keratoplasty






Case	Pre-CK Surgical History	Pre-CK UCVA	Pre-CK MR (BCVA)	Pre-CK Keratometry	Pre-CK Pachymetry (microns)	CK Treatment	PO-CK UCVA	PO-CK MR (BCVA)	PO-CK Keratometry
1	LASIK (free flap), flap reposition, flap lift & epithelial removal	20/50	+3.75-5.50X150 (20/30)	48.25/41.25X153	509		20/30	+0.50-1.00x175 (20/25)	48.0/44.0 x 160
2	LASIK (striae, Map Dot Fingerprint Dystrophy), PTK	20/25	+1.00-1.50X135 (20/20)	40.5/39.25X150	558		20/20	Plano-0.75X155 (20/20)	42.0/41.25X175
3	LASIK, retx LASIK, retx LASIK (striae), flap lift & smooth X2, flap suture	20/200	+1.75 (20/20)	38.75/38.5X90	444		20/40	+0.50-1.00x65 (20/25)	40.0/39.5X85
4	LASIK (thin flap), retx LASIK	20/100	+1.75-6.00X155 (20/25)	42.5/40.5X162	537		20/50	+0.75-1.00X135 (20/30)	
5	LASIK (thin cornea)	20/40	+3.25 (20/20)	35.25/35.25 spherical	385		20/25	Plano-0.75X115 (20/20)	38.0/37.5X105

Figure 4. Summary of the 5 case reports, including preoperative conductive keratoplasty (CK) data, CK surgical strategy, and postoperative outcomes BCVA = best spectacle-corrected visual acuity; MR = manifest refraction; PO = postoperative; PTK = phototherapeutic keratectomy; retx = retreatment; UCVA = uncorrected visual acuity.

Rigid gas-permeable contact lens overrefraction provided 20/20 vision and resolved patient symptoms. Keratometry was 42.50/40.50 × 160° with mild distortion, and topographic analysis showed 1.63 D of irregular astigmatism.

Given the thin flap and irregular astigmatism, CK was performed. Using topographic guidance to treat the different hemimeridians of astigmatism, 2 CK spots straddling the 155° meridian superiorly and 3 spots straddling the 145° meridian inferiorly were applied at an 8-mm optic zone diameter. Intraoperative keratometry was 44.00/41.00 × 60°. Three hours after CK, keratometry measurement remained fairly stable, with the flat topographic astigmatism axis measuring 2.66 × 53 (Fig 6). Three weeks later, UCVA was 20/40 and manifest refraction of -0.25/-0.75 × 5° provided 20/30 vision.

At 3 months postoperatively, regression of the CK effect was noted. Uncorrected VA was 20/50, with manifest refraction of +1.00/-3.75 × 150° giving 20/30. Keratometry was 43.00/41.75 × 155°. Therefore, CK retreatment was performed. Five CK spots were applied, 3 spots superiorly spanning the 155° meridian and 2 spots inferiorly straddling 150° at an optical zone of 8 mm. Intraoperative keratometry was 46.00/41.00 × 55°. The patient reported immediate improvement in VA to 20/30.

Two weeks postoperatively, UCVA remained 20/30. Six months later, UCVA was 20/100 and manifest refraction had regressed to +1.25/-5.00 × 160° with 20/30 VA. Keratometry was 42.0/41.75 × 160°. Therefore, a third CK retreatment was done. Three spots straddling the 160° meridian superiorly and 3 spots straddling the 145° meridian inferiorly were now applied at a 7-mm optical zone. Intraoperative keratometry measured 47.0/41.0 × 75°. Two months postoperatively, UCVA had improved to 20/40. Manifest refraction was +0.75/-0.75 × 92°, and BSCVA was 20/30. Four months later, manifest refraction was stable at +0.75/-1.00 × 135°.

Case 5 (Thin Cornea; Hyperopia)

A 47-year-old male was referred for consultation after having undergone bilateral myopic LASIK of approximately -5.50 D in

the right eye and -6.50 D in the left eye. Both eyes showed marked overcorrections. The worse left eye was 20/40 uncorrected. Manifest refraction of +3.25 D improved vision to 20/20, and keratometry assessment was 35.25 D spherical. Ultrasonic pachymetry measurement was 389 μm.

Because further excimer laser surgery was contraindicated due to the patient's corneal thickness, CK was performed. Sixteen spots were circumferentially placed, 8 each at optical zone diameters of 7 mm and 8 mm. Immediately after treatment, keratometry measurement was 40.75 D spherical. The postoperative period was uneventful. Uncorrected VA improved to 20/25 and remained stable 6 months after surgery. At this time, refraction was plano/-0.75 × 115°, giving 20/20.

Successful CK treatment in the right eye also was performed for a post-LASIK overcorrection of +1.75 D. Sixteen spots were circumferentially placed, 8 each at optical zone diameters of 8 mm and 9 mm. Uncorrected VA improved to 20/20 and remained stable at 6 months with a refraction of plano.

Discussion

Potential Advantages and Disadvantages of Conductive Keratoplasty

The treatment of hyperopia or hyperopia with astigmatism after other refractive surgery procedures is a potentially useful application of the CK procedure.^{20,21} In addition, CK offers unique advantages to patients who have encountered complications during initial refractive surgery. In particular, it allows for correction of hyperopia, hyperopic astigmatism, and irregular astigmatism in some cases in which further flap manipulation or additional laser ablation is undesirable. Such cases may include thin corneas, thin flaps, corneas with successfully treated striae, corneas with epithelial basement membrane dystrophy or surface disorders, and eyes that have had multiple surgeries.

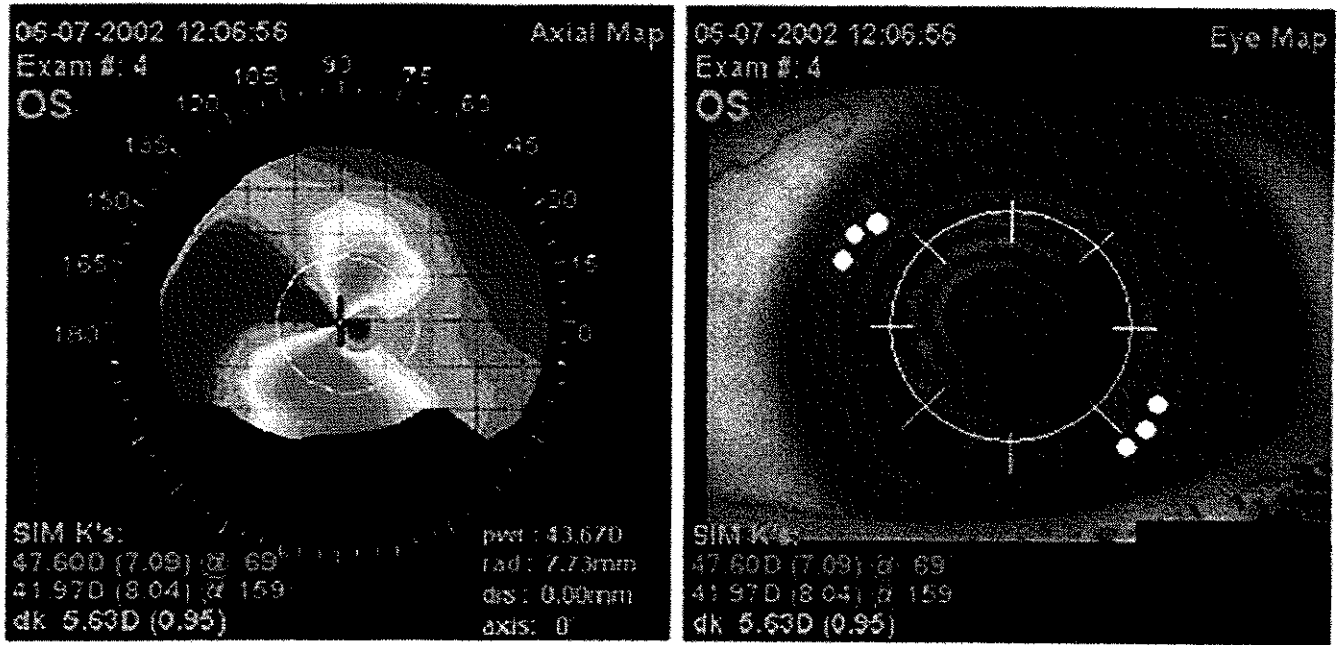


Figure 5. Case 1. Left, Preoperative conductive keratoplasty (CK) axial topography map. Right, Hirsch's ring image with overlaid CK treatment schematic. Note that the superimposed ring represents the 7-mm optical zone, and the tips of the radial hash marks represent the 6- and 8-mm zones. Depicted spots are at a 90-degree angle along the 6-mm axis of astigmatism. D = diopters; dis = distance; dk = difference in keratometry; K = keratometry; OS = left eye; pwr = power; rad = radius; SIM = simulated.

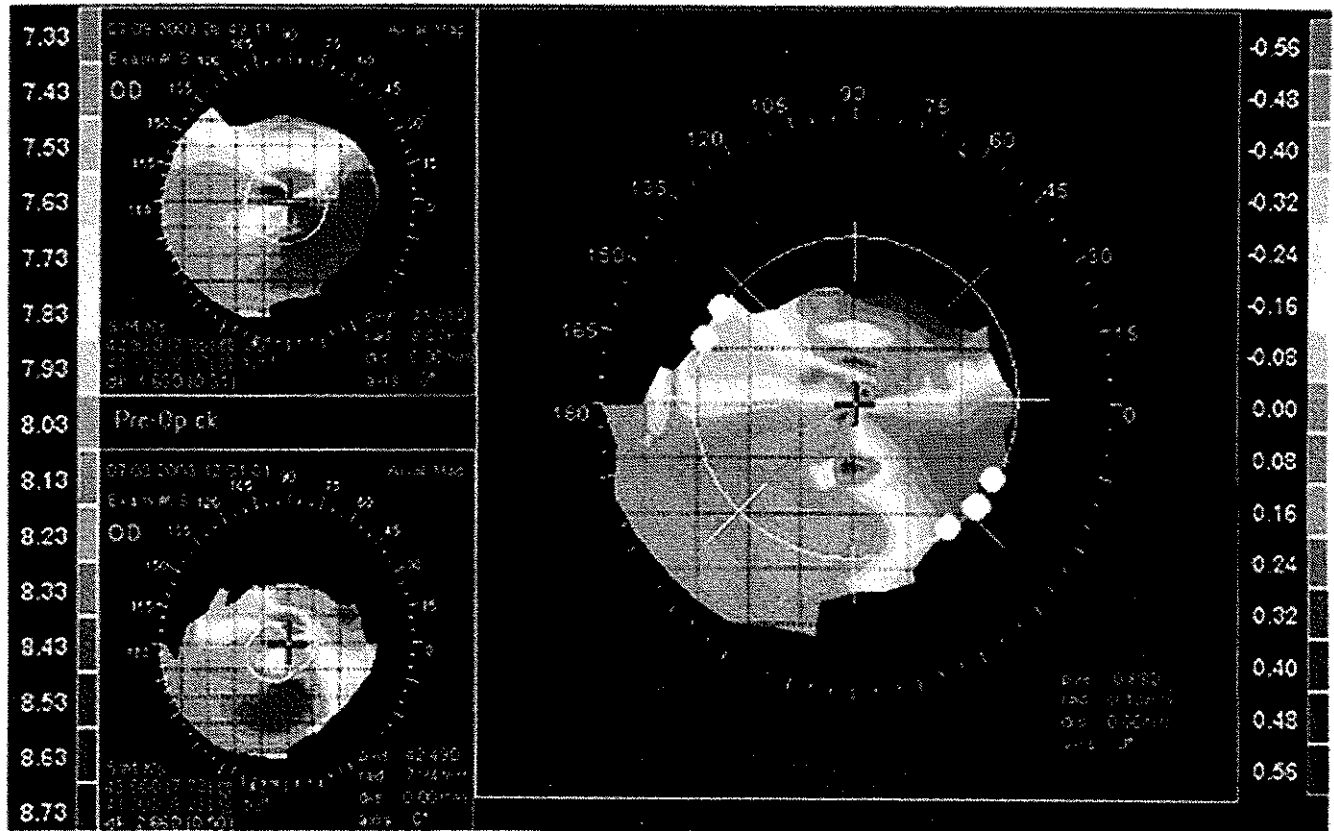


Figure 6. Case 3. Upper left, Preoperative conductive keratoplasty (CK) axial topography map. Lower left, Three-axis postoperative CK axial topography map. Right, Difference topography map with overlaid CK treatment schematic. Note steepening in the axis of CK application. D = diopters; dis = distance; dk = difference in keratometry; K = keratometry; OS = left eye; pwr = power; rad = radius; SIM = simulated.

For instance, after procedures involving a free cap or thin flap, such as cases 1 and 4, CK provides a means of surgically treating residual hyperopia and/or astigmatism without violating the compromised flap. Cases 2 and 3 are illustrative examples of other situations in which further surgical handling of the flap would be an unattractive option, given the successful resolution of flap striae with previous procedures. Interestingly, reports indicate that, although PTK treatments for striae have achieved success, they may also induce a hyperopic shift that would necessitate further surgical treatment to attain emmetropia.¹⁰ Conductive keratoplasty offers a solution for residual hyperopic correction in such cases. Finally, case 5 illustrates a hyperopic overcorrection after LASIK where further laser ablation is contraindicated because of corneal thinning and the risk of consequent ectasia.^{1,2,22}

Surface ablation is another option for treatment of residual hyperopia with or without astigmatism in some cases in which flap manipulation is to be avoided. In comparison, CK allows for a quicker healing process without the associated discomforts and potential morbidities of corneal re-epithelialization after PRK. Moreover, the CK spot application can be titrated until the desired correction is achieved. Such a multistep plan may be a more conservative approach, especially in eyes that have had less than optimal responses to previous surgical treatment. Additional treatment spots can be applied easily at a later date without great inconvenience to the patient if further correction is necessary. However, the implications of repeated treatments in the same area are as yet unclear.

Contrasting with these benefits are potential downsides of the procedure. As seen in this report, many eyes did require second and third treatments for either lack of achieving the complete desired initial effect or regression of treatment effect. This high rate of retreatment should be noted by both the surgeon and the potential patient. Similarly, results can vary and are not assured of being positive. In general, though, frank complications or undesired side effects seem to be rare.

Surgical Strategy and Nomogram

We have found that the treatment effect after both PRK and LASIK is approximately double that in previously untreated corneas. Thus, in such cases we have modified the recommended nomogram, which is based on native hyperopia in surgically untreated eyes, to avoid overcorrection. Each case is approached with a conservative treatment plan that is augmented as suggested by intraoperative keratometry. Thus, CK in the postsurgical setting is somewhat of an art that is not entirely predictable in preoperative planning.

The cause of the enhanced CK effect is likely biomechanical. Patients who have had previous excimer laser surgery have a postoperative corneal thickness that is centrally less than normal but peripherally unchanged. In a recent unpublished analysis of 1624 patients presenting for refractive surgery in our practice, the mean corneal thickness measured using ultrasound pachymetry was 546 (± 35) μm , which corroborates reports in the literature.^{23,24} The average pre-CK pachymetry measurement in this series was

460 μm —thus, on average, 86 μm thinner than normal. It seems that the circumferential collagen contracture produced by CK spots placed in the midperiphery has a more profound central steepening effect when the central cornea has been thinned, likely secondary to a decreased modulus of elasticity. Parenthetically, it should be noted that the CK spots are placed in the unablated or minimally ablated midperiphery and that the surgeon preoperatively should assure adequate corneal thickness in the area of actual spot application before proceeding. Alternatively, it has been suggested that a change in the structural relationship between the anterior and posterior lamellae from previous surgery may influence the response to the radiofrequency energy.²¹

Based on our experience, we propose that the application of CK spots be approached conservatively. In general, the anticipated result is twice that of the standard nomogram. Thus, optic zone diameters of 8 or 9 mm are often used as a starting point for treatment, compared with the standard 6-, 7-, and 8-mm optic zone diameters in untreated eyes. For example, our patient in case 5 who had a residual corneal thickness of 385 μm (LASIK) underwent a 16-spot treatment at diameters of 7 and 8 mm for an attempted correction of +3.25 D. In comparison, in a patient with native hyperopia a 32-spot treatment would be recommended to achieve the same degree of correction.

Keratometry measurements are taken intraoperatively to determine if further treatment is required. In general, we aim for modest overcorrection (approximately 125%–150% of desired correction) as measured intraoperatively by keratometry to anticipate relaxation of the corneal effect in the early postoperative phase.

Astigmatism Strategy

In theory, shrinking the collagen lamellae with a CK spot will decrease the chord length of the cornea in the meridian of application, hence steepening the cornea in that axis.²⁵ Indeed, calculations suggest that there will be a meridian steepening of 1 D for each 23 μm of decreased chord length.²⁶ In addition, focal shrinkage in a hemimeridian would be expected to move the cornea apex away from the application.²⁷

Therefore, CK spots are placed in the appropriate flat hemimeridians in patients with both regular and irregular astigmatism. We have noted 2 features of meridionally placed CK spots for astigmatism in the postoperative setting. First, they induce a large magnitude of correction. Thus, treatment should be planned cautiously, starting at relatively wide optical zone diameters (e.g., 8 or 9 mm). Second, there tends to be regression. Thus, we aim for approximately 150% to 200% correction at surgery in anticipation of corneal remodeling. Again, treatment is monitored by intraoperative keratometry, Placido's disc imagery, or videokeratography.

Irregular astigmatism resulting from LASIK and PRK complications presents a unique challenge.^{28–30} The recent introduction of custom wavefront-guided ablations provides a potential surgical therapy for irregularly shaped corneas. However, current wavefront technology limits treatments to

moderate degrees of astigmatism and reproducible wave-front patterns, eliminating many of the patients most in need of rehabilitative care. Because CK spots can be individually placed, the procedure affords a strategy for treating some cases of irregular astigmatism. For instance, in case 4, 2 spots straddling the 155° axis superiorly and 3 spots straddling the 145° axis inferiorly provided treatment along the non-orthogonal flat meridians as identified by topography analysis. Similarly, case 1 showed an objectively improved optical surface after CK treatment as measured by the topographically derived corneal uniformity index.

Conductive keratoplasty seems to be an effective procedure for treating some cases of hyperopic astigmatism after excimer laser surgeries, particularly in situations where further flap manipulation or laser treatment is contraindicated. However, the surgeon must be aware of the need for intraoperative assessment of effect, possible unpredictability, and frequent regression. It is important to be conservative in the initial treatment plan, with titration of surgery as judged by intraoperative measurements. Notwithstanding, complications seem to be rare and results often satisfactory in situations not amenable to other rehabilitative surgeries.

References

- Lui MM, Silas MA, Fugishima H. Complications of photorefractive keratectomy and laser keratomileusis. *J Refract Surg* 2003;19(suppl):S247-9.
- Ambrosio R Jr, Wilson SE. Complications of laser in situ keratomileusis: etiology, prevention, and treatment. *J Refract Surg* 2001;17:350-79.
- Stulting RD, Carr JD, Thompson KP, et al. Complications of laser in situ keratomileusis for the correction of myopia. *Ophthalmology* 1999;106:13-20.
- Lin RT, Maloney RK. Flap complications associated with lamellar refractive surgery. *Am J Ophthalmol* 1999;127:129-36.
- Tham VM, Maloney RK. Microkeratome complications of laser in situ keratomileusis. *Ophthalmology* 2000;107:920-4.
- Jacobs JM, Taravella MJ. Incidence of intraoperative flap complications in laser in situ keratomileusis. *J Cataract Refract Surg* 2002;28:23-8.
- Gimbel HV, Anderson Penno EE, van Westenbrugge JA, et al. Incidence and management of intraoperative and early postoperative complications in 1000 consecutive laser in situ keratomileusis cases. *Ophthalmology* 1998;105:1839-47, discussion 1847-8.
- Alio JL, Perez-Santonja JJ, Tervo I, et al. Postoperative inflammation, microbial complications, and wound healing following laser in situ keratomileusis. *J Refract Surg* 2000;16:523-38.
- Hersh PS, Steinert RF, Brint SF, Summit PRK-LASIK Study Group. Photorefractive keratectomy versus laser in situ keratomileusis: comparison of optical side effects. *Ophthalmology* 2000;107:925-33.
- Steinert RF, Ashrafzadeh A, Hersh PS. Results of phototherapeutic keratectomy in the management of flap striae after LASIK. *Ophthalmology* 2004;111:740-6.
- von Kulajta P, Stark WJ, O'Brien IP. Management of flap striae. *Int Ophthalmol Clin* 2000;40:87-92.
- Hersh PS, Fry KL, Bishop DS. Incidence and associations of retreatment after LASIK. *Ophthalmology* 2003;110:748-54.
- Pearce JA. Corneal reshaping by radiofrequency current: numerical model studies. In: Ryan TP, ed. *Thermal Treatment of Tissue: Energy Delivery and Assessment*. Bellingham, WA: SPIE; 2001:109-18.
- Sporl E, Genth U, Schmalzfuss K, Seiler F. Thermomechanical behavior of the cornea. *Ger J Ophthalmol* 1996;5:322-7.
- Pearce JA, Thomsen S. Rate process analysis of thermal damage. In: Welch AJ, van Gemert MJC, eds. *Optical-Thermal Response of Laser Irradiated Tissue*. New York: Plenum Press; 1995:573-6.
- Mendez A, Mendez Noble A. Conductive keratoplasty for the correction of hyperopia. In: Sher NA, ed. *Surgery for Hyperopia and Presbyopia*. Baltimore: Williams and Wilkins; 1997:163-71.
- Asbell PA, Maloney RK, Davidorf J, et al. Conductive Keratoplasty Study Group. Conductive keratoplasty for the correction of hyperopia. *Trans Am Ophthalmol Soc* 2001;99:79-84, discussion 84-7.
- McDonald MB, Davidorf J, Maloney RK, et al. Conductive keratoplasty for the correction of low to moderate hyperopia: 1-year results on 54 eyes. *Ophthalmology* 2002;109:637-49.
- McDonald MB, Hersh PS, Manche EE, Maloney RK, et al. Conductive Keratoplasty United States Investigators Group. Conductive keratoplasty for the correction of low to moderate hyperopia: U.S. clinical trial 1-year results on 355 eyes. *Ophthalmology* 2002;109:1978-89.
- Pallikaris IG, Naoumidi IL, Astyrakakis NI. Conductive keratoplasty to correct hyperopic astigmatism. *J Refract Surg* 2003;19:425-32.
- Comaish IF, Lawless MA. Conductive keratoplasty to correct residual hyperopia after corneal surgery. *J Cataract Refract Surg* 2003;29:202-6.
- Randleman JB, Russell B, Ward MA, et al. Risk factors and prognosis for corneal ectasia after LASIK. *Ophthalmology* 2003;110:267-75.
- Doughty MJ, Zaman ML. Human corneal thickness and its impact on intraocular pressure measures: a review and meta-analysis approach. *Surv Ophthalmol* 2000;44:367-408.
- Marsich MM, Bullimore MA. The repeatability of corneal thickness measures. *Cornea* 2000;19:792-5.
- Rowsey JJ. Ten caveats in keratorefractive surgery. *Ophthalmology* 1983;90:148-55.
- Blaker JW, Hersh PS. Theoretical and clinical effect of preoperative corneal curvature on excimer laser photorefractive keratectomy for myopia. *J Refract Corneal Surg* 1994;10:571-4.
- Rowsey JJ. Corneal laceration repair: topographic considerations and suturing techniques. In: Shingleton BJ, Hersh PS, Kenyon KR, et al, eds. *Eye Trauma*. St. Louis: Mosby Yearbook; 1991:160-3.
- Hersh PS, Scher KS, Irani R, Summit PRK-LASIK Study Group. Corneal topography of photorefractive keratectomy versus laser in situ keratomileusis. *Ophthalmology* 1998;105:612-9.
- Hersh PS, Abbassi R, Summit PRK-LASIK Study Group. Surgically induced astigmatism after photorefractive keratectomy and laser in situ keratomileusis. *J Cataract Refract Surg* 1999;25:389-98.
- Schwartz-Goldstein BH, Hersh PS, Summit Photorefractive Keratectomy Topography Study Group. Corneal topography of phase III excimer laser photorefractive keratectomy. Optical zone concentration analysis. *Ophthalmology* 1995;102:951-62.